

OPEN

Precannulated Fenestrated Endovascular Aneurysm Repair Using Guidewire Fixator

A Novel Method Using the Liungman Guidewire Fixator

Linus Bosaeus, MSc,* Kevin Mani, MD, PhD,†
Anders Wanhainen, MD, PhD,† and Krister Liungman, MD, PhD†

Objective: By using a guidewire fixator, the distal guidewire position can be secured in an artery. This new principle enables a method for fenestrated endovascular aortic repair where the connection between the aortic branches and the stent graft fenestrations is made before inserting and deploying the stent graft.

Methods: This is conducted using a fenestrated stent graft with preloaded catheters, through which the prepositioned and distally secured guidewires from the branches are inserted.

Results: This report covers the method when implementing a single fenestration stent graft in pig.

Conclusions: Successful tests with single and dual fenestrated grafts have been conducted in pigs.

Key Words: Guidewire fixator, Fenestrated endovascular aneurysm repair (f-EVAR), Aortic aneurysm, Stent graft.

(*Innovations* 2017;12:265–268)



Video clip is available online.

Accepted for publication May 13, 2017.

From the *Endovascular Development Ltd, Uppsala, Sweden; and †Department of Surgical Sciences, Uppsala University, Uppsala, Sweden.

A video clip is available for this article. Direct URL citations appear in the printed text and are provided in the HTML and PDF versions of this article on the journal's Web site (www.innovjournal.com).

Supported by Vinnova Research (2012-00374) and Endovascular Development (556783-0673), Uppsala, Sweden.

Disclosures: Linus Bosaeus, MSc, is employed by Endovascular Development Ltd, Uppsala, Sweden. Krister Liungman, MD, PhD, is the founder and has ownership in Endovascular Development, Ltd, that owns the intellectual rights to the Liungman Guidewire Fixator. Kevin Mani, MD, PhD, and Anders Wanhainen, MD, PhD, declare no conflicts of interest.

Address correspondence and reprint requests to Linus Bosaeus, MSc, Endovascular Development Ltd, Vasagatan 5B, 753 13 Uppsala, Sweden. E-mail: linus.bosaeus@endovab.com.

Copyright © 2017 The Author(s). Published by Wolters Kluwer Health, Inc. on behalf of the International Society for Minimally Invasive Cardiothoracic Surgery

This is an open-access article distributed under the terms of the Creative Commons Attribution-Non Commercial-No Derivatives License 4.0 (CCBY-NC-ND), where it is permissible to download and share the work provided it is properly cited. The work cannot be changed in any way or used commercially without permission from the journal.

ISSN: 1556-9845/17/1204-0265

Endovascular therapy has developed rapidly during the last 20 years. Most formally surgical vascular procedures are now performed by endovascular techniques.^{1–3} Endovascular techniques are increasingly used in complex situations and challenging anatomy, with combination of multiple wires, accesses, and hybrid procedures.

A well-recognized problem during visceral and aortic arch catheterization is the difficulty in achieving stable wire position in challenging and tortuous anatomy and the risk of losing a position during parallel endovascular work in the aorta. This problem can be encountered during carotid catheterization, during stent graft treatment in the branched part of the aorta, during visceral catheterization for treatment of occlusive arterial lesions, and during attempts for treatment of gastrointestinal or trauma hemorrhage. Unstable wire position may increase the risk of complications, due to prolonged procedure, dissection, and procedure failure.

In the present method for Branched or Fenestrated Endovascular Aortic Repair (f-EVAR), the aortic branches are catheterized after the main graft has been deployed. This requires high precision and geometrical alignment, including custom-made stent grafts.

METHODS

This report describes a simplistic case of a single fenestration f-EVAR in a pig model under anesthesia. Ethical approval from the committee of animal research ethics, Uppsala University, was granted on April 01, 2013.

Proposed and demonstrated in this report is a new method made possible by a new medical device, the Liungman Guidewire Fixator (LGF), that temporarily secures the distal end of a guidewire in an artery while maintaining arterial blood flow. By prepositioning and securing guidewires in the aortic branches, a stent graft with preloaded catheters through the fenestrations can be guided into position over the secured guidewires. Thus, the cumbersome steps of finding the aortic branches through the fenestrations, post stent graft deployment are eliminated.

The LGF is a temporary fixator that secures the distal end of a 0.035-in guidewire in an artery while maintaining blood flow. The device is an integrated assembly of three essential elements, a fixating element, a guidewire, and a retrieval catheter (Fig. 1).

The LGF is delivered and retrieved through a 7F sheath and will at rest produce a limited radial force to secure the guidewire position. The radial force increase if tension is applied (Fig. 2).

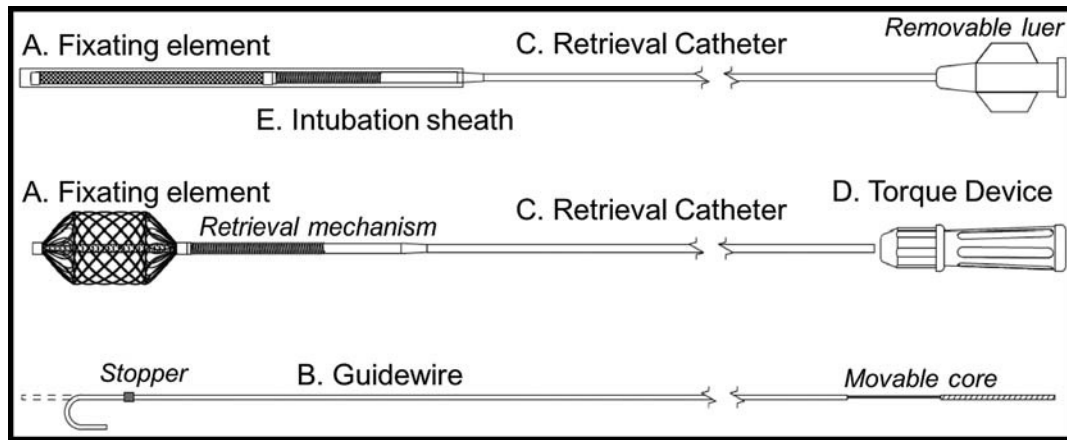


FIGURE 1. Fixator assembly. A, Self-expandable Nitinol fixation element. B, 0.035-in guidewire fitted with a distal stopper that engages with the fixation element. C, Retrieval catheter that is used to delivery and retrieve the fixator through a sheath. D, Torque device to enable easy rotation for detachment and attachment during delivery and retrieval. E, Transparent tube in which the fixator is delivered to access the sheath membrane.

The precannulation method for f-EVAR using the LGF requires a fenestrated stent graft with preloaded catheters lined through the fenestrations and accessible at the intersection between the sheath and the dilator. In this case, the stent graft, an Iliac extension graft (Cook Medical Europe, Bjaeverskov, Denmark), was modified in-house with one fenestration. The delivery system was modified to include the prelined catheters.

The treatment method is based on the following four main steps: (1) catheterization of the aortic branch and deployment of the LGF, (2) insertion of the stent graft over the prepositioned guidewires, (3) stent graft deployment and fenestration alignment, and (4) retrieval of the LGF and insertion of the bridging stent graft.

RESULTS

In the first step, the right renal artery was catheterized and the fixator was inserted into the artery to temporarily secure the guidewire position. In the second step, a Lunderqvist stiff guidewire (Cook Medical Europe, Bjaeverskov, Denmark) was inserted in the aorta for guiding delivery of the stent graft in the usual manner. Before inserting the stent graft, the LGF guidewire was lined through the preloaded catheter in a retrograde manner until accessible at the proximal end of the delivery system. The stent graft was then railroaded over the two guidewires until in position at the renal branch. The LGF guidewire consequently formed a loop above the top of the delivery sheath. See Figure 3 and Video Supplemental Digital Content 1 (<http://links.lww.com/INNOV/A145>).

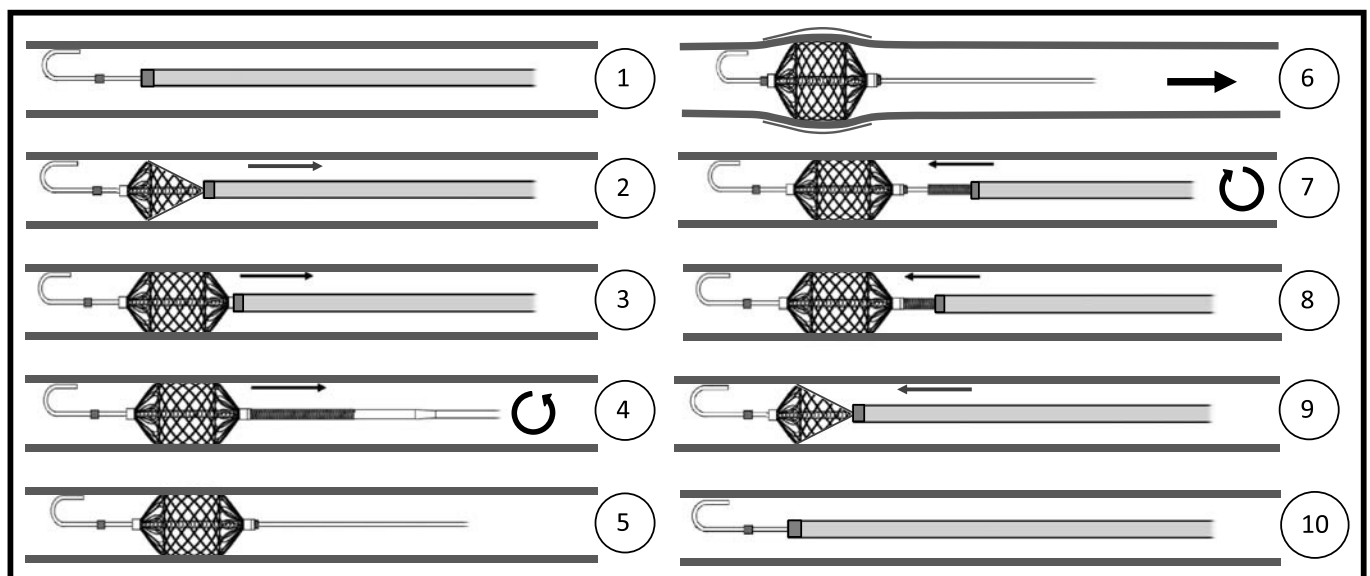


FIGURE 2. Fixator functionality. 1, Placement of sheath and LGF guidewire. 2–3, Positioning of the fixation element using the catheter, deployment by retraction of the sheath. 4, Detaching the fixator by counter clockwise rotation on the retrieval catheter. 5, Moderate radial force secures wire position at rest. 6, Distal stopper interaction causes increased anchoring force through expansion upon guidewire tension. 7–10, Fixator retrieval by reversing the delivery steps.

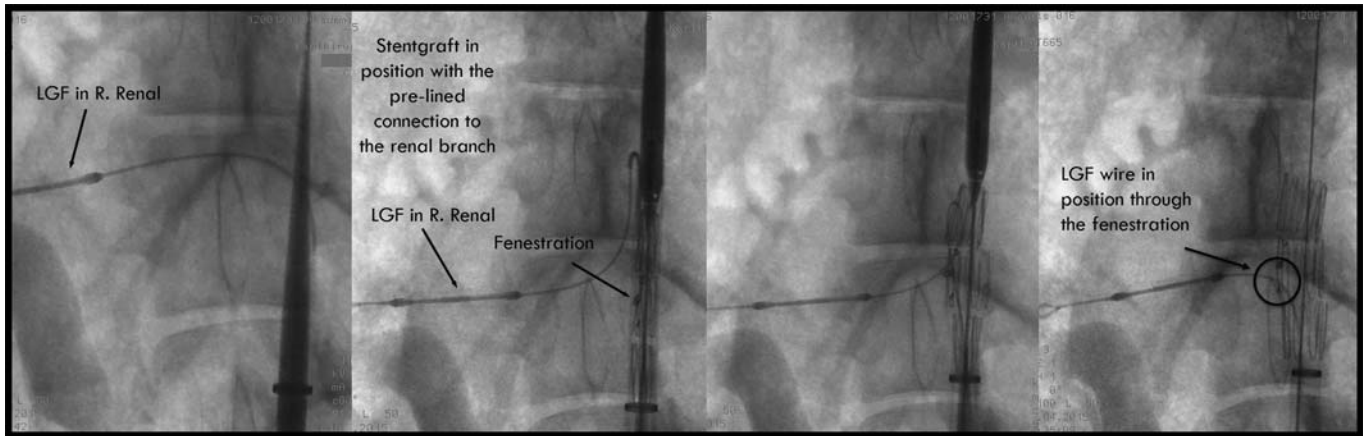


FIGURE 3. First, stent graft insertion over the main guiding wire and the LGF guidewire positioned in the renal branch. Second, stent graft in position over the renal branch. Third, stent graft is partially deployed and the LGF guidewire is pulled down to align with the renal branch. Fourth, The fenestration is aligned with the renal branch and the stent graft is deployed completely.

In the third step, the stent graft was first partially deployed by retraction of the sheath in a conventional manner. Once the fenestration was exposed, the LGF guidewire was pulled to align the fenestration with the branch. The stent graft position was adjusted followed by complete deployment. See Figure 3 and Video Supplemental Digital Content 1 (<http://links.lww.com/INNOV/A145>).

In the fourth and final step, the guidewire fixator was removed while the guidewire remained in place. A bridging balloon expandable Advanta stent graft (Atrium Europe, Mijdrecht, Netherlands) was inserted over the LGF guidewire and positioned through the fenestration. A final angiography completed the procedure.

DISCUSSION

This demonstration was conducted in a pig model. Consequently, the clinical application cannot yet be fully assessed. The small aortic dimension, approximately 15 mm, and the absence of an aortic aneurysm ruled out the use of conventional grafts, wherefore a smaller iliac extension stent graft was used and modified in-house. In addition, the delivery system had to be modified to allow for the new method with the preloaded catheter.

The principles in this new method are based on the features provided by the guidewire fixator. The same treatment method can be applied to f-EVAR cases with more than one fenestration. The main difference is that two or more guidewires require an additional procedure before inserting the stent graft, where multiple wires are controlled to prevent entanglement.

In the fourth and final step of the method, the fixator was retrieved before inserting the bridging covered graft because of the short common renal branch in the pig model. There are, however, no procedural limitations in reversing the step and retrieve the fixator after the bridging graft has been positioned.

The method of precannulation f-EVAR aims to reduce the procedural duration by eliminating the present time-consuming and cumbersome step of finding the aortic branches through the fenestrations in the graft. Re-entering the sheath into the target artery for placement of the bridging stent graft is simplified by the opportunity to add tension to guidewire stiffness. These advantages reduce the need for perfect alignment between the fenestration and the aortic branch, possibly enabling a wider use of standardized fenestrated stent grafts.

The device risks associated with arterial trauma, dissection, and thrombotic occlusion have been separately investigated in animal models.⁴

The presented report demonstrates that a new method for facilitated f-EVAR is possible by use of a novel device, a guidewire fixator. Distal guidewire fixation enables precannulation of the aortic branches. The device and method must undergo further clinical trial to prove the method. The LGF is at this time CE approved but not approved by the Food and Drug Administration and not yet available for sale.

ACKNOWLEDGMENTS

The authors thank the Swedish innovation agency Vinnova Research for support and Hedenstierna Laboratories, Uppsala, Sweden, for laboratory support.

REFERENCES

- Greenberg RK, Sternbergh WC III, Makaroun M, et al. Intermediate results of a United States multicenter trial of fenestrated endograft repair for juxtarenal abdominal aortic aneurysms. *J Vasc Surg.* 2009;50:730–737.
- Amiot S, Haulon S, Becquemin JP, et al. Fenestrated endovascular grafting: the French multicentre experience. *Eur J Vasc Endovasc Surg.* 2010;39:537–544.
- Pennywell DJ, Tan TW, Zhang WW. Optimal management of infrainguinal arterial occlusive disease. *Vasc Health Risk Manag.* 2014;10:599–608.
- Bosaesus L, Mani K, Wanhainen A, Liungman K. Novel device, a temporary guidewire fixator. *Vascular.* 2016;24:604–609.

CLINICAL PERSPECTIVE

The report by Bosaeus et al details a novel technical approach for facilitating cannulation during fenestrated endovascular aneurysm repair (f-EVAR). The challenge with these procedures is first aligning the fenestration in the main body with the branch vessel, cannulating the branch vessel with a guidewire and then delivering a covered stent through the fenestration into the branch vessel. In addition to the challenge of cannulating the side branch with a guidewire, there is often difficulty in anchoring the guidewire adequately into the branch vessel to facilitate tracking of a rigid balloon-mounted covered stent into the side branch. Factors affecting the ability to track the stent are both degree of angulation at which the side branch originates off the aorta and depth of “purchase” of the guidewire into the side branch.

In this article, the Liungman Guidewire Fixator was shown to represent a significant advancement in facilitating f-EVAR procedures. The ability to “anchor” a precannulated guidewire into a branch vessel enabled the operator to deliver the necessary stent to the branch vessel in an efficient manner. The technical challenge of delivering stents to side branches is not unique to f-EVAR procedures, and there is a possibility that the approach described in this article may be used for other endovascular procedures such as thoracic endovascular aortic repair (TEVAR) and branched TEVAR procedures.