





## SHORT COMMUNICATION

# Low-grade diffusely infiltrative tumour (LGDIT), SMARCB1-mutant: A clinical and histopathological distinct entity showing epigenetic similarity with ATRT-MYC

Martin Hasselblatt<sup>1</sup>  | Christian Thomas<sup>1</sup> | Aniello Federico<sup>2,3</sup> | Susanne Bens<sup>4</sup> | Mats Hellström<sup>5</sup> | Olivera Casar-Borota<sup>5,6</sup>  | Uwe Kordes<sup>7</sup> | Julia E. Neumann<sup>8,9</sup>  | Matthias Dottermusch<sup>8,9</sup> | Fausto J. Rodriguez<sup>10</sup>  | Andrea C. Lo<sup>11</sup> | Sylvia Cheng<sup>12</sup> | Glenda Hendson<sup>13</sup> | Juliette Hukin<sup>12</sup> | Christian Hartmann<sup>14</sup> | Arend Koch<sup>15</sup> | David Capper<sup>15,16</sup> | Reiner Siebert<sup>4</sup> | Werner Paulus<sup>1</sup> | Karolina Nemes<sup>17</sup> | Pascal D. Johann<sup>2,3,17</sup> | Michael C. Frühwald<sup>17</sup> | Marcel Kool<sup>2,3,18</sup>

<sup>1</sup>Institute of Neuropathology, University Hospital Münster, Münster, Germany

<sup>2</sup>Hopp Children's Cancer Center (KITZ), Heidelberg, Germany

<sup>3</sup>Division of Paediatric Neurooncology, German Cancer Research Center (DKFZ) and German Cancer Consortium (DKTK), Heidelberg, Germany

<sup>4</sup>Institute of Human Genetics, Ulm University and Ulm University Medical Center, Ulm, Germany

<sup>5</sup>Department of Immunology, Genetics and Pathology, Rudbeck Laboratory, Uppsala University, Uppsala, Sweden

<sup>6</sup>Department of Clinical Pathology, Uppsala University Hospital, Uppsala, Sweden

<sup>7</sup>Department of Pediatric Hematology and Oncology, University Medical Center, Hamburg, Germany

<sup>8</sup>Institute of Neuropathology, University Medical Center, Hamburg, Germany

<sup>9</sup>Center for Molecular Neurobiology Hamburg (ZMNH), University Medical Center Hamburg-Eppendorf, Hamburg, Germany

<sup>10</sup>Department of Pathology, The Johns Hopkins University School of Medicine, Baltimore, Maryland, USA

<sup>11</sup>Radiation Oncology, British Columbia Cancer and University of British Columbia, Vancouver, Canada

<sup>12</sup>Division of Hematology, Oncology and BMT, Department of Pediatrics, University of British Columbia, Vancouver, Canada

<sup>13</sup>Department of Pathology, BC Women and Children's Hospital, Vancouver, Canada

<sup>14</sup>Department of Neuropathology, Institute of Pathology, Hannover Medical School, Hannover, Germany

<sup>15</sup>Department of Neuropathology, Charité - Universitätsmedizin Berlin, Corporate Member of Freie Universität Berlin and Humboldt-Universität zu Berlin, Berlin, Germany

<sup>16</sup>German Cancer Consortium (DKTK), Partner Site Berlin, German Cancer Research Center (DKFZ), Heidelberg, Germany

<sup>17</sup>Pediatric and Adolescent Medicine, Swabian Childrens' Cancer Center, University Childrens' Hospital Medical Center Augsburg and EU-RHAB Registry, Augsburg, Germany

<sup>18</sup>Princess Máxima Center for Pediatric Oncology, Utrecht, Netherlands

## Correspondence

Martin Hasselblatt, Institute of Neuropathology, University Hospital Münster, Pottkamp 2, 48149 Münster, Germany.

Email: hasselblatt@uni-muenster.de

## Funding information

The Brain Tumour Charity, UK; IZKF Münster, Grant/Award Number: Ha3/017/20

**KEYWORDS:** atypical teratoid/rhabdoid tumour, central nervous system low-grade diffusely infiltrative tumour with INI1 deficiency, DNA methylation profiling, neuropathology

Martin Hasselblatt and Christian Thomas contributed equally.

This is an open access article under the terms of the Creative Commons Attribution-NonCommercial-NoDerivs License, which permits use and distribution in any medium, provided the original work is properly cited, the use is non-commercial and no modifications or adaptations are made.

© 2022 The Authors. *Neuropathology and Applied Neurobiology* published by John Wiley & Sons Ltd on behalf of British Neuropathological Society.

Atypical teratoid/rhabdoid tumour (AT/RT) is a highly malignant central nervous system tumour characterised by loss of SMARCB1/INI1 protein expression [1]. Most AT/RTs occur in infants, but older children and adults may also be affected. AT/RT comprises three molecular subgroups, ATRT-SHH, ATRT-TYR and ATRT-MYC [2]. The median age of ATRT-MYC patients is older [2], and many AT/RTs diagnosed in adolescents and adults represent ATRT-MYC [3]. In older patients, secondary AT/RTs developing from tumours with retained SMARCB1/INI1 staining such as pleomorphic xanthoastrocytoma [4] and ganglioglioma [5] are also on record. Recently, central nervous system low-grade diffusely infiltrative tumour with INI1 deficiency (CNS LGDIT-INI1) has been described as a low-grade lesion with diffuse growth of small inconspicuous SMARCB1/INI1-deficient tumour cells and a background of neurons and reactive astrocytes, which has the potential to progress to AT/RT [6]. DNA methylation profiling performed in one case yielded similarity with ATRT-MYC [6], but the relationship of CNS LGDIT-INI1 and ATRT-MYC has not been further examined. Here, we confirm that CNS LGDIT-INI1 represents a clinical and histopathological distinct entity and provide evidence for epigenetic similarity of CNS LGDIT-INI1 with ATRT-MYC. In line with recent developments of WHO nomenclature, we propose to change the name from CNS LGDIT-INI1 to LGDIT, SMARCB1-mutant.

Six consult cases of LGDIT, SMARCB1-mutant (including one recently published case), were retrieved from the archives of the Institute of Neuropathology Münster (Table 1). The median age of the four males and two females was 16 years (range: 10–28 years). All tumours were of supratentorial location. Histopathologically, cases represented tumours of low to moderate cellularity and diffuse growth of inconspicuous small SMARCB1-deficient tumour cells and reactive pleomorphic neuronal cells and glial cells with retained SMARCB1-staining in the background as originally described by Nobusawa et al. [6] (Figure 1A,C). Tumour cells stained positive for vimentin (6/6 cases) and CD34 (3/6 cases) but were negative for GFAP, S100, actin, desmin, epithelial membrane antigen, cytokeratins (MN116), neuronal antigens (synaptophysin, NeuN) and Olig2 (0/4), CD45 (0/3) and CD68 (0/3). Pleomorphic glial cells in the background stained positive for GFAP and S100. Mitoses were absent, and proliferative activity was low to moderate in most cases (median Ki67/MIB1 index 8%, Figure 1E). In addition, two cases also showed a high-grade component composed of densely packed rhabdoid tumour cells showing SMARCB1/INI1 loss as well as increased mitotic and proliferative activity (Figure 1B,D,F). Low grade cases had initially been diagnosed as diffuse astrocytoma, desmoplastic myxoid tumour, SMARCB1-mutant (DMT) or SMARCB1-deficient tumour, not elsewhere classified. In the two cases featuring a high-grade component, the possibility of AT/RT with a ganglioglioma component had been considered. Virtual slides of all cases of the series are available online ([https://omero-imaging.uni-muenster.de/webclient/img\\_detail/42361/](https://omero-imaging.uni-muenster.de/webclient/img_detail/42361/)).

Fluorescence in situ hybridization (FISH) performed in five cases revealed a homozygous deletion of the *SMARCB1* locus. None of the

## Key Points

- Low-grade diffusely infiltrative tumour (LGDIT), SMARCB1-mutant, represents a rare supratentorial tumour with loss of SMARCB1/INI1 expression encountered in older children and young adults.
- Inconspicuous tumour cells and lack of specific markers pose a diagnostic challenge and highlight the diagnostic value of DNA methylation profiling.
- DNA methylation profiles of LGDIT, SMARCB1-mutant, group together but show epigenetic similarity with atypical teratoid/rhabdoid tumours of the molecular subgroup ATRT-MYC.
- The potential of LGDIT, SMARCB1-mutant, to progress to atypical teratoid/rhabdoid tumour warrants careful follow-up examination and possibly early therapeutic intervention.

six cases showed a *BRAF-V600E* mutation using Sanger sequencing. After DNA isolation from formalin-fixed paraffin-embedded tumour samples, purification and bisulfite conversion using standard protocols, all six cases were subjected to DNA methylation profiling using MethylationEPIC BeadChip array (Illumina Inc., San Diego, CA). Copy-number variation analysis from methylation array data confirmed the presence of a homozygous *SMARCB1* deletion in all six cases. Apart from a second more distal 22q deletion present in three cases, various chromosomal losses, but no recurrent chromosomal alterations, were noted (Figure S1). Using DNA methylation-based classification and the Heidelberg Brain Tumour Classifier (version v11b4) [8], all tumours were classified as ATRT-MYC (median calibrated score: 0.97). Next, *t*-distributed stochastic neighbour embedding (*t*-SNE) analysis was performed in comparison with DNA methylation profiles of 112 AT/RT samples (29 ATRT-MYC, 37 ATRT-TYR and 46 ATRT-SHH), 58 malignant rhabdoid tumours of the kidney, 8 poorly differentiated chordomas, SMARCB1-mutant, and 6 desmoplastic myxoid tumours, SMARCB1-mutant [9]. DNA methylation profiles of the six LGDIT, SMARCB1-mutant, grouped together in proximity to ATRT-MYC (Figure 1g). Furthermore, unsupervised hierarchical clustering results confirmed epigenetic similarity of LGDIT, SMARCB1-mutant, and ATRT-MYC (Figure S2). Follow-up information was available for four cases (including the two cases with a high-grade component). Patients responded well to therapy and experienced stable disease or complete remission after an observation time of three to 56 months (Table 1).

Our findings confirm that LGDIT, SMARCB1-mutant, represents a clinical and histological distinct entity. Of note, LGDIT, SMARCB1-mutant, lacks the polyphenotypic expression profile encountered in AT/RT. Inconspicuous tumour cells and lack of

**TABLE 1** Patient characteristics

	Sex	Age (years)	Location	AT/RT component	Radiotherapy	Chemotherapy	Follow-up (months)	Outcome
Case 1	Female	18	Hemispheric	Yes	Proton irradiation (1.8 ≥ 59.4 RBE)	Alternating ICE and VCA	56	complete remission
Case 2	Female	28	Hemispheric	No				
Case 3	Male	20	Left hemispheric	No				
Case 4	Male	10	Right hemispheric	No	none	None	11	stable disease
Case 5 [7]	Male	14	Parieto-occipital	Yes	local radiation	MTX intraventricular, Doxorubicin, ICE, VCA	9	complete remission
Case 6	Male	10	Parietal	No	radiation planned after 3rd high dose cycle	2 cycles of ICE chemotherapy, now receiving second of 2 high dose chemotherapy cycles with carboplatin and thiotepa and stem cell rescue as per COG ACNS 0333	3	complete remission

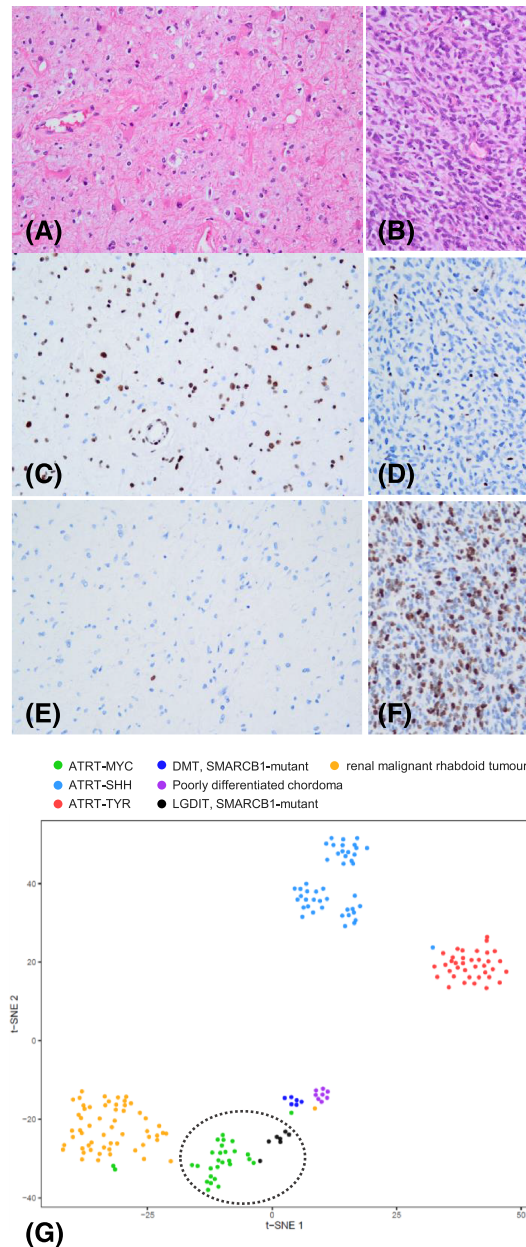
specific diagnostic markers pose a diagnostic challenge and highlight the value of DNA methylation profiling in this setting. From our experience, the possibility of LGDIT, SMARCB1-mutant, should be considered in any low-grade lesion with epigenetic similarity with AT/RT. This holds especially true for supratentorial tumours in older children and young adults, an age group where AT/RTs are only rarely encountered.

The exact relationship between LGDIT, SMARCB1-mutant, and AT/RT remains to be determined. The view that LGDIT, SMARCB1-mutant, may represent an early stage of ATRT-MYC could be supported by the epigenetic similarity with ATRT-MYC, but also by the fact that two LGDIT, SMARCB1-mutant, featured a high-grade AT/RT component. Furthermore, malignant progression to AT/RT has been described in two of three cases of the original series [6] and in another tumour with histological features of LGDIT, SMARCB1-mutant, as long as 10 years after the initial diagnosis [10]. Taken into account the relatively short follow-up of the present series, it cannot be excluded that eventually all LGDIT, SMARCB1-mutant, may progress to AT/RT. Therefore, careful follow-up examinations are warranted, and the possibility of early therapeutic intervention needs to be considered.

On the other hand, because DNA methylation profiles of LGDIT, SMARCB1-mutant, grouped closely together and the number of cases of the present series was relatively small, it cannot be excluded that epigenetic distinction of LGDIT, SMARCB1-mutant, and ATRT-MYC may be possible once a larger number of cases is available for examination. The possibility that LGDIT, SMARCB1-mutant, and ATRT-MYC may originate from different

cells of origin needs also to be considered, because epigenetic similarity of LGDIT, SMARCB1-mutant, and ATRT-MYC could rather represent a consequence of the well documented effects [11] of SMARCB1/INI1 loss on the epigenome. The older median age of patients harbouring LGDIT, SMARCB1-mutant, as compared to AT/RT could point toward a different vulnerable time period for tumourigenesis. Other potential mechanisms involved in the biology of LGDIT, SMARCB1-mutant, may include decreased susceptibility of tumour cells to SMARCB1/INI1 loss and possibly even interactions with pleomorphic neighbouring cells showing retained SMARCB1/INI1 staining. Pleomorphic glial cells in the background stained positive for GFAP and S100 and showed retained (normal) SMARCB1/INI1 staining. Most likely, they represent reactive non-neoplastic cells. We have also considered the possibility of a pre-existing low-grade glioma, but from our experience in AT/RT with molecular features of pleomorphic xanthoastrocytoma [4], such tumours retain the epigenetic and genetic signature of the primary lesion, which seems not to be the case in LGDIT, SMARCB1-mutant.

The cell of origin of LGDIT, SMARCB1-mutant (and ultimately ATRT-MYC), remains to be determined. Interestingly, in malignant rhabdoid tumours of the kidney [12], which show epigenetic similarity with ATRT-MYC [13], neighbouring Schwann cells have been shown to partly share genetic alterations of the malignant rhabdoid tumour, including homozygous deletions of the SMARCB1 locus [12], suggesting that SMARCB1/INI1 loss may not be sufficient to drive the development of malignant rhabdoid tumours [12].



**FIGURE 1** Histopathological and molecular features of LGDIT, SMARCB1-mutant. Histopathologically, LGDIT, SMARCB1-mutant, represents a diffuse low-grade lesion composed of inconspicuous small tumour cells (H&E stain, A). Note pleomorphic glial and neuronal cells in the background. Tumour cells show loss of SMARCB1/INI1 expression, while SMARCB1/INI1 is retained in nuclei of pleomorphic glial and neuronal cells (C) and proliferative activity (Ki67/MIB) is low (E). In contrast, the high-grade component encountered in two of the cases shows rhabdoid tumour cells with brisk mitotic activity (B), loss of SMARCB1/INI1 expression (D) and increased proliferative activity (F), that is, characteristic features of AT/RT. On t-SNE analysis, DNA methylation profiles of the six CNS LGDIT, SMARCB1-mutant, group together in proximity to ATRT-MYC (G). t-SNE analysis was performed on the 5,389 most variable methylation probes (standard deviation > 0.26) across the whole dataset. Pairwise sample distances were calculated using 1 minus the weighted Pearson correlation coefficient as the distance measure. The resulting distance matrix was used to perform the t-SNE analysis. The following non-default parameter adjustments were made: theta = 0, is\_distance = T, pca = F, max\_iter = 2,000, perplexity = 10

In conclusion, this series confirms that LGDIT, SMARCB1-mutant, is a clinically and histologically distinct entity. LGDIT, SMARCB1-mutant, shows epigenetic similarity with ATRT-MYC and has the potential for malignant progression.

#### ACKNOWLEDGEMENTS

The study was further supported by IZKF Münster (Ha3/017/20) and “The Everest Centre for Research into Paediatric Low Grade Brain Tumours” (The Brain Tumour Charity, UK).

## CONFLICT OF INTEREST

The authors have no competing interest to declare.

## AUTHOR CONTRIBUTIONS

MH and CT designed the study. All authors were involved in the acquisition, analysis or interpretation of data for the work. MH drafted the manuscript, and all other co-authors revised it and approved the final version.

## ETHICS STATEMENT

Cases were retrieved from the archives of the Institute of Neuropathology Münster. The tumour bank of the Institute of Neuropathology Münster has received continuous local ethics committee approval (Ethics committee of the University Hospital Münster). Patients or the guardians gave informed consent for the scientific use of archival materials. Patient level data included are consistent with governance approvals/consents.

## PEER REVIEW

The peer review history for this article is available at <https://publons.com/publon/10.1111/nan.12797>.

## DATA AVAILABILITY STATEMENT

The data that support the findings of this study are available from the corresponding author upon reasonable request.

## ORCID

Martin Hasselblatt  <https://orcid.org/0000-0003-2707-8484>

Olivera Casar-Borota  <https://orcid.org/0000-0001-7376-7331>

Julia E. Neumann  <https://orcid.org/0000-0002-1162-8771>

Fausto J. Rodriguez  <https://orcid.org/0000-0001-8662-1219>

## REFERENCES

- Frühwald MC, Biegel JA, Bourdeaut F, Roberts CW, Chi SN. Atypical teratoid/rhabdoid tumors-current concepts, advances in biology, and potential future therapies. *Neuro Oncol*. 2016;18(6):764-778. doi:10.1093/neuonc/nov264
- Ho B, Johann PD, Grabovska Y, et al. Molecular subgrouping of atypical teratoid/rhabdoid tumors-a reinvestigation and current consensus. *Neuro Oncol*. 2020;22(5):613-624. doi:10.1093/neuonc/noz235
- Johann PD, Bens S, Oyen F, et al. Sellar region atypical teratoid/rhabdoid tumors (ATRT) in adults display DNA methylation profiles of the ATRT-MYC subgroup. *Am J Surg Pathol*. 2018;42(4):506-511. doi:10.1097/PAS.0000000000001023
- Thomas C, Federico A, Sill M, et al. Atypical teratoid/rhabdoid tumor (AT/RT) with molecular features of pleomorphic xanthoastrocytoma.

- Am J Surg Pathol*. 2021;45(9):1228-1234. doi:10.1097/PAS.0000000000001694
- Kleinschmidt-DeMasters BK, Birks DK, Aisner DL, Hankinson TC, Rosenblum MK. Atypical teratoid/rhabdoid tumor arising in a ganglioglioma: genetic characterization. *Am J Surg Pathol*. 2011;35(12):1894-1901. doi:10.1097/PAS.0b013e3182382a3f
- Nobusawa S, Nakata S, Nakano Y, et al. CNS low-grade diffusely infiltrative tumors with INI1 deficiency, possessing a high propensity to progress to secondary INI1-deficient rhabdoid tumors. *Am J Surg Pathol*. 2020;44(11):1459-1468. doi:10.1097/PAS.0000000000001520
- Dottermusch M, Schumann Y, Hasselblatt M, Neumann JE. Spatial molecular profiling of a central nervous system low-grade diffusely infiltrative tumor with INI1 deficiency (CNS LGDIT-INI1) featuring a high grade AT/RT component. *Neuropathol Appl Neurobiol*. 2021; Online ahead of print. doi:10.1111/nan.12777
- Capper D, Jones DTW, Sill M, et al. DNA methylation-based classification of central nervous system tumours. *Nature*. 2018;555(7697):469-474. doi:10.1038/nature26000
- Thomas C, Wefers A, Bens S, et al. Desmoplastic myxoid tumor, SMARCB1-mutant: clinical, histopathological and molecular characterization of a pineal region tumor encountered in adolescents and adults. *Acta Neuropathol*. 2020;139(2):277-286. doi:10.1007/s00401-019-02094-w
- Schweizer Y, Meszaros Z, Jones DTW, et al. Molecular transition of an adult low-grade brain tumor to an atypical teratoid/rhabdoid tumor over a time-course of 14 years. *J Neuropathol Exp Neurol*. 2017;76(8):655-664. doi:10.1093/jnen/nlx044
- Erkek S, Johann PD, Finetti MA, et al. Comprehensive analysis of chromatin states in atypical teratoid/rhabdoid tumor identifies diverging roles for SWI/SNF and polycomb in gene regulation. *Cancer Cell*. 2019;35:95-110 e8. doi:10.1016/j.ccell.2018.11.014
- Custers L, Khabirova E, Coorens THH, et al. Somatic mutations and single-cell transcriptomes reveal the root of malignant rhabdoid tumours. *Nat Commun*. 2021;12(1):1407. doi:10.1038/s41467-021-21675-6
- Chun HE, Johann PD, Milne K, et al. Identification and analyses of extra-cranial and cranial rhabdoid tumor molecular subgroups reveal tumors with cytotoxic T cell infiltration. *Cell Rep*. 2019;29:2338-2354.e7. doi:10.1016/j.celrep.2019.10.013

## SUPPORTING INFORMATION

Additional supporting information may be found in the online version of the article at the publisher's website.

**How to cite this article:** Hasselblatt M, Thomas C, Federico A, et al. Low-grade diffusely infiltrative tumour (LGDIT), SMARCB1-mutant: A clinical and histopathological distinct entity showing epigenetic similarity with ATRT-MYC. *Neuropathol Appl Neurobiol*. 2022;48(4):e12797. doi:10.1111/nan.12797