

# Aorto-cutaneous fistula of the ascending aorta—case report and a literature review of endovascular management

Sinead Gormley, MBBCh, BAO,<sup>a,c</sup> Zubayr Zaman, MBBS, FRCR,<sup>b</sup> Kevin Mani, MD, PhD, FEBVS,<sup>a,d,e</sup> and Manar Khashram, FRACS, PhD,<sup>a,d</sup> *Hamilton and Auckland, New Zealand*

## ABSTRACT

Aorto-cutaneous fistulas are an unusual and life-threatening complication after aortic surgery. We present the case of an endovascular intervention for an aorto-cutaneous fistula of the ascending aorta that was intended to be a bridge to definitive surgical treatment and report a literature review. A 56-year-old woman had a previous Bentall's procedure and mitral valve annuloplasty in 2016. Four years later she re-presented with an infective pseudoaneurysm of the distal anastomosis of the ascending aortic graft, with aorto-cutaneous fistulation. She was at high risk for a revision operation and required optimization before a major open surgery. A thoracic endovascular aortic repair stent graft (Valiant Navion; Medtronic Inc) was implanted to exclude the distal anastomotic pseudoaneurysm. Two months later she re-presented with a new infected pseudoaneurysm at the proximal end of the previously implanted stent graft, and a further thoracic endovascular aortic repair was undertaken. (J Vasc Surg Cases Innov Tech 2023;9:1-6.)

**Keywords:** Aorto-cutaneous fistula; Aortic pseudoaneurysm; Ascending aorta; Endovascular treatment; TEVAR; Case report

Aorto-cutaneous fistulas and aortic pseudoaneurysms of the ascending aorta after aortic surgery are rare and pose potentially catastrophic consequences. These conditions require rapid diagnosis and urgent life-saving surgical intervention. Endovascular solutions offer the possibility to mitigate death in the short term in certain situations and may serve as a bridge in acute clinical scenarios to optimize a patient before an attempt for definitive surgical intervention. Informed patient consent was obtained for publication of this case report and all images.

## CASE

A 52-year-old woman presented acutely with worsening shortness of breath and treated as an exacerbation of heart failure. An echocardiogram demonstrated a 5.4-cm aortic root dilated ascending aorta and a bicuspid aortic valve with moderate mixed aortic valve disease

as well as mild mitral regurgitation, which was thought to be functional. She had no prior medical history except for a penicillin allergy and no known family history of aortopathy. She was a regular smoker but denied illicit drug use.

She had a Bentall's procedure using a 27-mm bio-integral valve aortic bio-conduit and mitral valve annuloplasty. There were no complications in the postoperative period, and the sternotomy wound had healed in the 12 months after surgery. Four years later, she re-presented to a cardiothoracic clinic with a discharging sternal sinus, secondary to infection of the sternal wires with *Staphylococcus aureus* (methicillin-sensitive), resulting in chronic sternal osteomyelitis. This was managed with sternal wound debridement, removal of the superior infected sternal wires, antibiotics and negative pressure wound therapy, and then subsequent conventional dressings. The infectious disease team advised a course of co-trimoxazole for the treatment of this infection until complete wound closure was achieved.

Four weeks after removal of the superior sternal wires she re-presented acutely to hospital complaining of chest pain, dizziness, and multiple episodes of active bleeding from her sternal wound. On examination (height 176 cm, weight 55 kg), she was hemodynamically stable, with a swollen chronically infected sinus over her previous sternotomy scar with evidence of hematoma (Fig 1, A). Laboratory results demonstrated anemia with hemoglobin of 95 g/L, albumin 27 g/L, and raised inflammatory markers with white cell count of  $9 \times 10^9/L$ , platelet count of  $613 \times 10^9/L$ , and C-reactive protein 24 mg/L. A computed tomography (CT) angiogram

---

From the Department of Vascular & Endovascular Surgery,<sup>a</sup> and Department of Interventional Radiology,<sup>b</sup> Waikato Hospital Hamilton, Hamilton; Faculty of Medicine,<sup>c</sup> and Department of Surgery,<sup>d</sup> University of Auckland, Auckland; and the Department of Surgical Sciences, Section of Vascular Surgery, Uppsala University, Uppsala.<sup>e</sup>

Author conflict of interest: none.

Correspondence: Sinead Gormley, MBBCh, BAO, Department of Vascular & Endovascular Surgery, Waikato Hospital, 183 Pembroke Street Hamilton, New Zealand 3204 (e-mail: [sineadgormley4@gmail.com](mailto:sineadgormley4@gmail.com)).

The editors and reviewers of this article have no relevant financial relationships to disclose per the Journal policy that requires reviewers to decline review of any manuscript for which they may have a conflict of interest.

2468-4287

© 2022 The Author(s). Published by Elsevier Inc. on behalf of Society for Vascular Surgery. This is an open access article under the CC BY-NC-ND license (<http://creativecommons.org/licenses/by-nc-nd/4.0/>).

<https://doi.org/10.1016/j.jvscit.2022.06.023>

demonstrated a pseudoaneurysm at the distal anastomosis of the ascending graft and rim-enhancing soft tissue surrounding the aorta. The appearances were in keeping with sternal wound infection having extended to the ascending aortic bio graft forming a pseudoaneurysm, with the development of an aorto-cutaneous fistula through the osteomyelitic sternum and to the infected skin sinus.

The patient's case was discussed at an aortic multidisciplinary team meeting involving vascular surgeons, interventional radiologists, cardiothoracic surgeons, cardiovascular anesthetists, and intensive care specialists. The definitive open repair contemplated was radial surgical debridement, removal of infective foreign material, and re-do Bentall's proximal arch replacement with or without removal of the mitral ring under deep hypothermic circulatory arrest. She was deemed high-risk and not fit to tolerate a re-do Bentall's operation at this point. Multiple risk factors were identified that would delay wound healing and postoperative recovery including malnourishment, low body mass index, significant smoking history, and multiple psychosocial issues that include a history of nonadherence to medical advice. The consensus was to exclude the pseudoaneurysm with an endovascular stent graft to the ascending aorta to manage the risk for exsanguination from repeat aorto-cutaneous fistula bleeding until a more definitive open surgery could be considered (Fig 1, B and C). Endovascular treatment was always intended to be used as a temporizing measure to optimize the patient before major cardiac revision surgery and to allow time for long-term antibiotics to suppress graft infection.

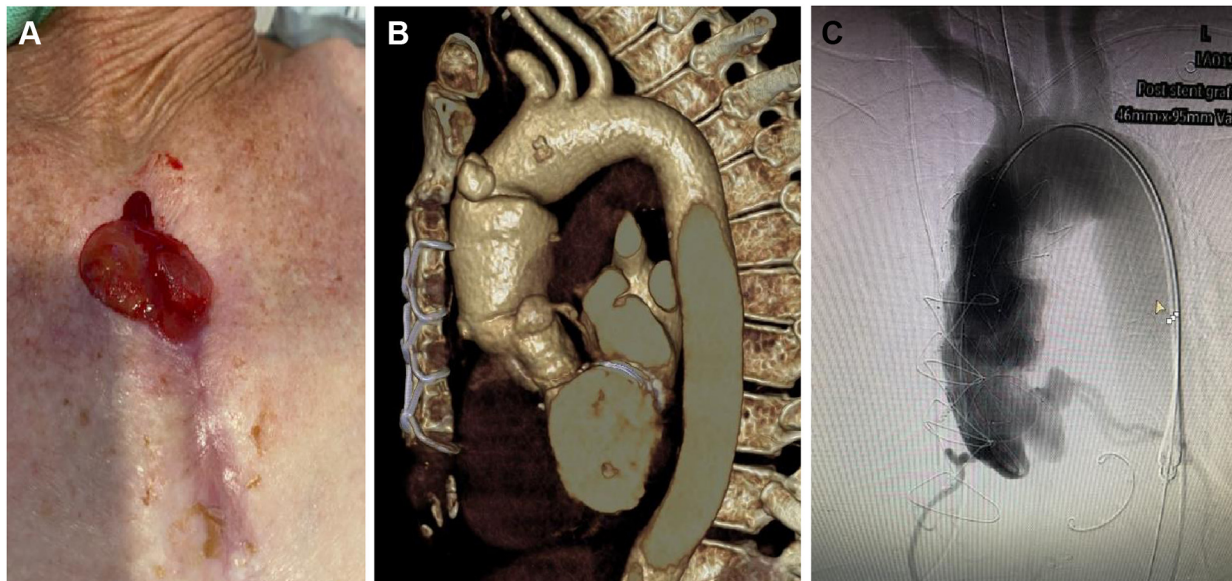
Anatomically, the pseudoaneurysm was located at the distal anastomosis of the ascending graft. The ascending graft proximal to the pseudoaneurysm was 43 mm in diameter, and the aorta distal to the pseudoaneurysm was 42 × 38 mm. The distance between the coronary arteries and the proximal end of the pseudoaneurysm was 53 mm, and the distance from the proximal end of the brachiocephalic trunk to the distal end of the pseudoaneurysm was 30 mm. Based on these measurements, a 46 mm × 46 mm 55-mm Valiant Navion stent graft (Medtronic Inc) was selected for exclusion of the pseudoaneurysm and flushed with rifampicin before insertion. Under general anesthetic, percutaneous femoral access was used and the stent was deployed under rapid pacing to 200 bpm and dilated after placement. A completion angiogram confirmed exclusion of the pseudoaneurysm under two imaging planes. The patient was woken up immediately after the procedure with no neurological deficits. A CT angiogram performed 48 hours later demonstrated successful covering of the pseudoaneurysm at the anterior aspect of the ascending aorta (Fig 2). The infectious disease team advised long-term antibiotics for the treatment of *S. aureus* mediastinitis based on radiological imaging

and clinical appearances of sternal wound breakdown. She was subsequently discharged 48 hours later. Her follow-up plan consisted of cardiothoracic and infectious disease clinic appointments at 2 weeks, vascular clinic appointment at 6 weeks with repeat CT angiography prior, and regular community nurse visits multiple times per week to perform wound dressing changes. Several measures were taken to optimize the patient during this bridging period to aortic revision surgery. These consisted of regular dietician assessments to improve nutrition and increase her weight, regular blood tests, and red blood cell transfusions and iron infusions to treat anemia along with psychological, psychiatric, and social work input to address the issues of medical noncompliance. She also had regular infectious disease follow-up in the community that included visits by a community pharmacist to ensure that she received long-term antibiotics to suppress graft infection.

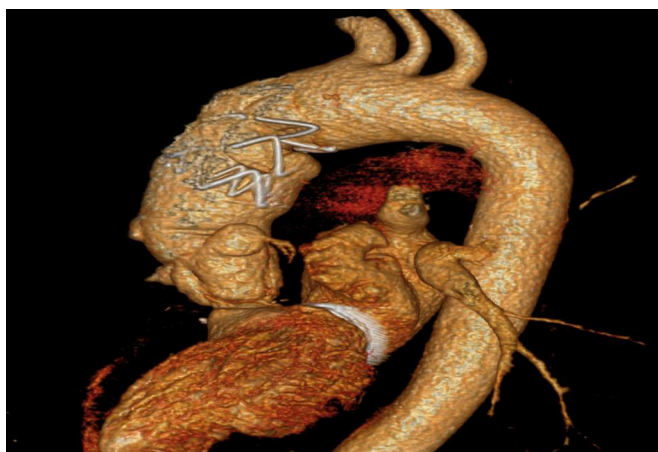Two months later she re-presented acutely in septic shock. Her observations showed a blood pressure of 75/51 mm Hg, heart rate of 127, respiratory rate of 27, and temperature of 40 °C, with bloods demonstrating a white cell count of  $19.7 \times 10^9/L$ , a C-reactive protein of 160 mg/L, and a lactate of 2.2 mmol/L. A CT angiogram demonstrated a new infected pseudoaneurysm at the proximal end of the previously implanted stent graft, still with intact ascending graft proximal to the pseudoaneurysm as a possible proximal landing zone for endovascular repair (Fig 3, A). A multidisciplinary meeting was held, the consensus of which was to perform a thoracic endovascular aortic repair with extension of the graft to just distal to the coronary arteries to exclude the pseudoaneurysm. An intraoperative transesophageal echocardiogram was performed that did not reveal any signs of vegetation's of the aortic valve.

The second ascending stent graft was performed percutaneously under general anesthesia. Because of the proximal landing zone of the stent graft being just distal to the coronary artery origins, the tip of the stent graft delivery system was to be inserted into the left ventricle. Hence, a 0.035 SAFARI wire (Medtronic Inc) was placed into the left ventricle for device delivery. From the left groin a pigtail catheter was placed just above the aortic valve. Again a Medtronic Valiant Navion 46 × 46 × 93 mm stent graft (Medtronic Inc) was flushed with rifampicin and was deployed under rapid cardiac pacing. Completion angiogram confirmed satisfactory stent position with exclusion of the pseudoaneurysm. The CT angiogram day 6 after surgery demonstrated that the pseudoaneurysm was successfully covered with the thoracic stent graft (Medtronic Inc) (Fig 3, B).

Multiple admissions were arranged by the cardiothoracic team for red blood cell transfusions and iron infusions due to blood loss through the sternotomy wound over a period of 6 months. Regular dietician input was obtained, and there were slow improvements in terms



**Fig 1.** Patient with aorto-cutaneous fistula. **A**, With intermittent bleeding, 5 years after ascending repair with bovine graft, due to graft infection and development of distal anastomosis expanding pseudoaneurysms. **B**, The patient was treated with implantation of the ascending aortic stent graft. **C**, Successfully covering the aneurysm as a bridging measure while being considered for further radical surgical intervention.



**Fig 2.** Computed tomography (CT) angiogram after the first thoracic endovascular aortic repair stent.

of nutritional status during that time. Specialist cardiac input from a cardiothoracic surgeon in another center that specializes in complex re-do aortic surgery was also obtained. She was assessed by this surgeon for a second opinion on surgical management. He made a potential operative plan for cardiac salvage surgery with an inpatient mortality risk of over 50%.

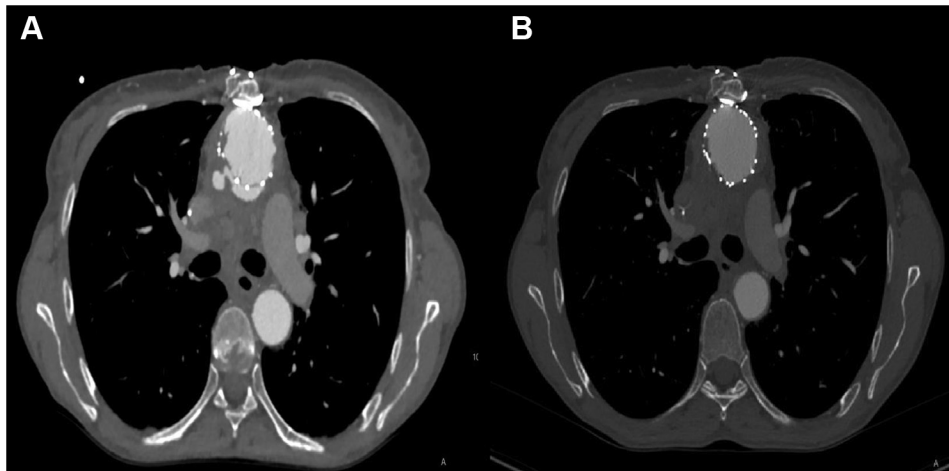
Three months later after the second thoracic endovascular aortic repair stent, the patient re-presented with sternal wound bleeding, hemoptysis, and dizziness. On admission her hemoglobin was 73 g/dL requiring transfusion. CT angiography demonstrated extension of the

pseudoaneurysm superior to the stent graft and up to the level of the brachiocephalic trunk, as well as an empyema (see Fig 4). The pseudoaneurysm was compressing the carina with a pouch concerning for an abscess developing between the airways. The aim of performing endovascular treatment until this stage was to act as a bridging therapy until she was optimized for definitive open aortic surgery. The patient subsequently made the decision not to proceed with any further surgery and declined antibiotic therapy. She was palliated and died 7 months after the first endovascular stent graft procedure.

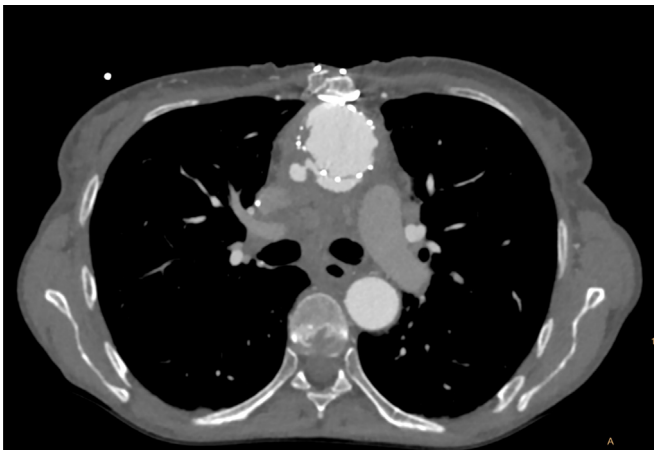## DISCUSSION

Traditionally, ascending aortic aneurysms or dissections are treated with open surgery, but endovascular techniques in selected patients have proven to be an acceptable bridge until a more definitive procedure can be undertaken in the context of infected endografts.

A literature search was conducted using Google Scholar, PubMed and Embase searching the following terms: aortocutaneous, fistula identified 13 relevant case reports (Table). The majority of the cases reported to date have had treatment by complex open surgery that was associated with a high mortality and represents a surgical challenge. The major challenges involve safe re-entry into the chest and adequate cerebral protection, and the critical risk is related to potential false aneurysm rupture that may lead to catastrophic bleeding. We have identified 2 other cases of an aorto-cutaneous fistula treated using an endovascular technique.



**Fig 3.** **A,** Computed tomography (CT) angiogram demonstrating recurrent pseudoaneurysm of the ascending aorta. **B,** CT angiogram demonstrating the second thoracic endovascular aortic repair graft.



**Fig 4.** Computed tomography (CT) angiography demonstrating extension of the pseudoaneurysm superior to the stent graft and up to the level of the brachiocephalic trunk. It appeared that the pseudoaneurysm was compressing the carina with a pouch concerning for an abscess developing between the airways.

Aortic surgery involving recurrent disease in the ascending aorta can be challenging to treat. There are several challenges with performing stent graft placement in the ascending aorta including appropriate graft selection, access and customizing the graft delivery system.<sup>14</sup> The normal length of the ascending aorta from the sinotubular junction to the brachiocephalic trunk is between 65 and 87 mm depending on age, hypertension, and measurement method.<sup>15</sup> This excludes the majority of the currently available off-the-shelf stent grafts due to length. However, the Medtronic Navion thoracic stent graft has a working length of 93 mm. Accessing the ascending aorta can also be challenging. In this case, the femoral artery was chosen as the access site,

but other supra-aortic branches can facilitate stent graft positioning and precision in deployment.<sup>14,16</sup>

The ascending aorta has specific anatomic and hemodynamic features that can pose a technical challenge. The high shear forces of blood through the aortic valve can make accurate stent placement in the ascending aorta difficult. Several techniques have been described to lower cardiac output and heart rate such as pharmacological manipulation of cardiac preload and contractility and rapid ventricular pacing. Because of the close proximity of the aortic valve, coronary arteries, and the brachiocephalic trunk, precise placement of the stent graft is essential. In addition, one must appreciate the curvature of the ascending aorta. There is a mismatch between the lengths of the inner and outer curvature, and the delivery device has to follow the curvature of the aortic arch and ascending aorta, which makes perpendicular placement of the stent graft challenging.<sup>15</sup> The presence of arch types can also complicate this approach and highlights the need for consideration of additional strategies such as hybrid open surgery and custom-made fenestrated or physician-modified stent grafts.<sup>13</sup>

## CONCLUSIONS

Endovascular treatment of aorto-cutaneous fistulas and pseudoaneurysms involving the ascending aorta offer the possibility to mitigate death in the short term in certain situations and may serve as a potential bridge to optimize a patient before an attempt for definitive surgical intervention. In this case, the patient made an informed decision not to proceed with open surgery closer to the time she was being reconsidered for it. We acknowledge that the durability of the endovascular stent graft in the ascending aorta is still unknown and will need to be analyzed in the future.

**Table.** Summary of literature search of the management of the aorto-cutaneous fistula

Author	Age/sex	Index aortic surgery	Time to aorto-cutaneous fistula	Management	Outcomes
Bridgewater et al, 1992 <sup>1</sup>	Case 1: 78 F Case 2: 60 M	Case 1: aortic valve surgery Case 2: interposition graft ascending aorta	Case 1: 8 years Case 2: 6 months	Case 1: open surgery Case 2: open surgery	Case 1: alive, discharged 3 weeks after surgery Case 2: alive, discharged home at 6 weeks
Panos et al, 1999 <sup>2</sup>	35 not reported	Congenital heart surgery	5 years	Open surgery	Alive, discharged from hospital 1 week later
Miguel et al, 2000 <sup>3</sup>	78 not reported	CABG complicated by ascending aorta dissection requiring prosthetic graft placement	20 months	Endovascular treatment	Alive at 1 year
Arsan et al, 2004 <sup>4</sup>	57 not reported	AVR and 4 vessel CABG	10 months	Open surgery	Dead
Yaliniz et al, 2005 <sup>5</sup>	65 M	CABG	9 months	Open surgery	Dead
Athanazio et al, 2007 <sup>6</sup>	60 M	Large thoracoabdominal aortic aneurysm	Not reported	Palliation	Dead, day 7 of hospital admission
Aydin et al, 2012 <sup>7</sup>	67 not reported	CABG and ascending aorta replacement for aortic dissection	5 years	Open surgery	Dead, day 3 after surgery
Al-Atassi et al, 2014 <sup>8</sup>	76 M	Repair of a Stanford type A aortic dissection using an ascending aortic Dacron graft	7 years	Open surgery	Unknown
Demondion et al, 2017 <sup>9</sup>	82 F	Ascending aortic replacement for Stanford type A aortic dissection	5 years	Open surgery	Unknown
Chan et al, 2018 <sup>10</sup>	76 M	Aortic arch replacement surgery using a Dacron graft	4 years	Open surgery	Alive at 18 months
Zhao et al, 2018 <sup>11</sup>	67 M	Ascending aorta and arch graft replacement for a Stanford type A aortic dissection	4 years	Open surgery	Died, day 3 after surgery
Triantafyllidis et al, 2020 <sup>12</sup>	69 F	Ascending aorta replacement for Stanford type A aortic dissection	2 years	During resuscitation external opening compression sutures of the fistula placed	Underwent whole body CT that did not demonstrate free aortic rupture
Yerram et al, 2021 <sup>13</sup>	57 F	Mechanical MVR for severe mitral valve stenosis and chronic rheumatic heart disease	2 years	Endovascular treatment	Dead

AVR, Aortic valve replacement; CABG, cardiopulmonary bypass graft; CT, computed tomography; F, female; M, male; MVR, mitral valve replacement.

## REFERENCES

1. Bridgewater BJ, Tsang V, Pepper J, Lennox SC. Aorto-cutaneous fistula: a rare complication of aortic surgery. *Thorac Cardiovasc Surg* 1992;40:45-7.
2. Panos A, Kalangos A, Murith N, Faidutti B. Aorta-cutaneous fistula as a rare complication of localized chronic mediastinitis. *Thorac Cardiovasc Surg* 1999;47:335-7.
3. Miguel B, Camilleri L, Gabrillargues J, Macheda B, Kubota H, Ravel A, et al. Coil embolization of a false aneurysm with aorto-cutaneous fistula after prosthetic graft replacement of the ascending aorta. *Eur J Radiol* 2000;34:57-9.
4. Arsan S, Yildirim T, Akgun S, Kurtoglu N. A mediastinal false aneurysm with aortocutaneous fistula. *Heart Surg Forum* 2004;7:41-2.
5. Yaliniz H, Tokcan A, Ulus T, Poyrazoglu H. Aorto-cutaneous fistula: complication of coronary artery bypass graft operation. *J Cardiovasc Surg (Torino)* 2005;46:596-7.
6. Athanazio DA, Athanazio PR, Schaer-Barbosa H. Aortocutaneous fistula complicating a pseudoaneurysm of the thoracic aorta—a necropsy report. *Cardiovasc Pathol* 2007;16:357-8.
7. Aydin U, Gorur A, Findik O, Canikoglu M, Kucukcerit T, Kocogullari CU. A rare complication: aorta-cutaneous fistula with abundant bleeding. *Heart Surg Forum* 2012;15:E323-5.
8. Al-Atassi T, Kimmaliardjuk D, Labinaz M, Dickie S, Rubens F. A novel approach to safe redo-sternotomy in a patient with aortocutaneous fistula from an infected ascending aorta graft. *Perfusion* 2014;29:373-4.
9. Demondion P, Verscheure D, Leprince P. Aorto-cutaneous fistula and false aneurysm of the ascending aorta five years after its prosthetic replacement for Stanford type A acute aortic dissection. *Aorta (Stamford)* 2017;5:57-60.
10. Chan BK, Turner PE, Kim S, Mojibian HR, Elefteriades JA, Narayan D. Phage treatment of an aortic graft infected with *Pseudomonas aeruginosa*. *Evol Med Public Health* 2018;2018:60-6.
11. Zhao C, Zhu Z, Zheng X, Liu K. Aorto-cutaneous fistula after surgical treatment of Stanford type A aortic dissection. *Int Heart J* 2018;59:223-5.
12. Triantafyllidis A, Paraskeva A, Boulas KA, Nathanailidou M, Chatzipourgianis K, Hatzigeorgiadis A. Aorto-cutaneous fistula from an infected ascending aorta graft resulting in massive hemorrhage after a Valsalva maneuver for a heavy weight lift. *Clin Case Rep* 2020;8:2289-90.
13. Yerram S, Vikrama A, Mahapatra S, Bhyravajhala S, Venkata Kumar R. Post-operative recurrent ascending aortic pseudoaneurysm with aorto-cutaneous fistula- endovascular management with an in-situ stent-graft fenestration for the innominate artery. *Ann Vasc Surg* 2021;75:534.e5-9.
14. Khashram M, Baimatova I, Laing A, Blake J, Khanafer A. Endovascular repair of a traumatic ascending aortic tear injury. *J Vasc Interv Radiol* 2016;27:1712-4.
15. Gottardi R, Buchholz S, Hegazy Y, Sodian R. Treatment of a massive pseudoaneurysm originating from the ascending aorta with an off-the-shelf stent graft. *Eur J Cardiothorac Surg* 2021;60:1234-6.
16. Gray BH, Langan EM III, Manos G, Bair L, Lysak SZ. Technical strategy for the endovascular management of ascending aortic pseudoaneurysm. *Ann Vasc Surg* 2012;26:734-8.

Submitted Mar 19, 2022; accepted Jun 30, 2022.