

ORIGINAL ARTICLE

Strabismus and refraction in non-syndromic craniosynostosis – A longitudinal study up to 5 years of age

Evangelia Ntoula¹  | Daniel Nowinski²  | Gerd Holmström¹  | Eva Larsson¹ 

¹Department of Surgical Sciences, Ophthalmology, Uppsala University, Uppsala, Sweden

²Department of Surgical Sciences, Plastic Surgery, Uppsala University, Uppsala, Sweden

Correspondence

Eva Larsson, Department of Surgical Sciences/Ophthalmology, Uppsala University, Uppsala S-751 85, Sweden. Email: eva.larsson@neuro.uu.se

Funding information

Ögonfonden; Stiftelsen Kronprinsessan Margaretas Arbetsnämnd för Synskadade

Abstract

Purpose: To evaluate the refractive outcome and strabismus at 5 years of age, in children operated for various types of non-syndromic craniosynostosis, and further analyse the refractive and strabismic development over time.

Methods: Eighty-nine children, who had undergone operations for non-syndromic craniosynostosis, were examined at 5 years of age. These children also underwent ophthalmological examination preoperatively and up to 1 year after the operation. An age-matched control group including 32 healthy children was also recruited.

Strabismus and eye motility were registered. Refraction was measured in cycloplegia.

Results: There was a difference regarding the refractive outcome between the different types of craniosynostosis. Higher values of hypermetropia were found in the metopic craniosynostosis group on both eyes. In the unicoronal craniosynostosis group, high values of hypermetropia and a higher degree of astigmatism were found on the side contralateral to the craniosynostosis. Strabismus was found in 11/88 children of whom 10/11 had unicoronal craniosynostosis. A vertical deviation on the side ipsilateral to the fused suture was highly prevalent (6/10 cases). Ophthalmological dysfunctions were rare in children operated for sagittal craniosynostosis.

Conclusion: Ocular manifestations such as strabismus, astigmatism and anisometropia were highly prevalent in children operated for unilateral coronal craniosynostosis. Children operated for metopic craniosynostosis had higher rates of hypermetropia. The screening and follow-up protocols need to be tailored with regard to the type of craniosynostosis.

KEYWORDS

craniofacial surgery, follow-up, ophthalmological outcome, orbital dysmorphology, refractive outcome, single-suture craniosynostosis, strabismus

1 | INTRODUCTION

Craniosynostosis is a congenital condition in which the premature fusion of one or more cranial sutures leads to characteristic cranial deformations. The prevalence of craniosynostosis is approximately 1 per 2000–2500 births worldwide (Governale, 2015), and in Sweden, 7.7 per 10000 births (Tarnow et al., 2022). It appears as isolated in the majority of cases or more rarely in association with a craniofacial or other genetic syndrome. Non-syndromic craniosynostosis typically involves fusion of one suture, also called isolated or single-suture

craniosynostosis, while syndromic craniosynostosis usually involves multiple sutures and often occurs with malformations of the cranial base and midface skeleton. The most common single-suture craniosynostosis is sagittal synostosis, followed by metopic synostosis, unilateral coronal synostosis and unilateral lambdoid synostosis (Gencarelli et al., 2016).

Oculomotor disorders and refractive errors in syndromic craniosynostosis are well described in the literature and are believed to be attributed to the orbital deformity per se (Hinds et al., 2022; Khan et al., 2003; Rafique Ali et al., 2022; Tay et al., 2006; Touzé et al., 2019).

This is an open access article under the terms of the [Creative Commons Attribution-NonCommercial-NoDerivs](https://creativecommons.org/licenses/by-nc-nd/4.0/) License, which permits use and distribution in any medium, provided the original work is properly cited, the use is non-commercial and no modifications or adaptations are made.

© 2023 The Authors. *Acta Ophthalmologica* published by John Wiley & Sons Ltd on behalf of Acta Ophthalmologica Scandinavica Foundation.

Recently, the focus has been directed at understanding the effects of non-syndromic craniosynostosis on ophthalmic manifestations. Numerous studies have documented the ophthalmological outcome in unilateral coronal craniosynostosis, such as strabismus, astigmatism and anisometropia (Chung et al., 2015; Gupta et al., 2003; Levy et al., 2007; Luo et al., 2020; Macintosh et al., 2007; Tarczy-Hornoch et al., 2008; Touzé et al., 2022).

Ophthalmic manifestations in other forms of non-syndromic craniosynostosis are less described; nonetheless, visual dysfunctions, strabismus, refractive errors and amblyopia have been reported (Denis, Genitori, Bardot, et al., 1994; Macintosh et al., 2011; Nguyen et al., 2016; Roider et al., 2021).

Early surgical intervention, before 1 year of age, is preferred in most cases of non-syndromic craniosynostosis in order to achieve the best correction of skull deformity and prevent intracranial hypertension (Ntoula et al., 2021). The surgical treatment in metopic and coronal craniosynostosis requires orbital skeleton remodelling, and the risk of iatrogenic ophthalmological dysfunction has been acknowledged (Elhusseiny et al., 2021; Gencarelli et al., 2016; Samra et al., 2015; Song et al., 2016; Yu et al., 2020).

In children treated for various types of non-syndromic craniosynostosis, there are only a few studies that attempt to systematically analyse ophthalmic abnormalities preoperatively and during the early postoperative course and further examine the long-term ophthalmological effects (Chung et al., 2015; Gupta et al., 2003; Macintosh et al., 2011).

In a previous study, we reported the ophthalmological findings in children with non-syndromic craniosynostosis pre- and postoperatively up to 12 months after surgery.

Children with sagittal craniosynostosis appeared to have a low prevalence of ophthalmic dysfunctions. Unicoronal craniosynostosis had the highest prevalence of strabismus, astigmatism and anisometropia, in agreement with previous studies (Ntoula et al., 2021).

The purpose of this study was to evaluate the refractive outcome and strabismus in 5-year-old children operated for various types of non-syndromic craniosynostosis, as well as to analyse the development over time.

2 | MATERIALS AND METHODS

This was a follow-up study of a cohort of children who underwent operations for various types of non-syndromic craniosynostosis at Uppsala Craniofacial Centre, Uppsala University Hospital, Sweden, between September 2012 and April 2019. These children were previously included in an analysis of ophthalmological examinations performed preoperatively and up to 1 year after the operation. Here, the same cohort was prospectively examined at 5 years of age as part of a protocolised multidisciplinary craniofacial assessment. The examinations were performed by a team of experienced orthoptists and paediatric ophthalmologists between April 2017 and June 2022. In the cases where the children did not attend the follow-up appointment, medical records regarding

refraction and orthoptic measurements at 5 years of age were retrieved from local hospitals. Children with craniosynostosis syndromes, such as Crouzon, Apert, Pfeiffer and Saethre–Chotzen syndromes, complex craniosynostosis or rare genetic syndromes, were excluded.

The study included 89 children 5 years of age (63 boys), out of whom 79 were examined at the Department of Ophthalmology, Uppsala University. Medical records from another 10 children, examined according to clinical practice in the local hospitals, were collected. Seventy-two children had a complete longitudinal follow-up, consisting of examination preoperatively, postoperatively 6–12 months after the surgery and at 5 years of age. Thirteen were examined preoperatively and at 5 years of age, and four were examined postoperatively and at 5 years of age.

An age-matched control group of 32 children without craniosynostosis, who underwent ophthalmological examination according to the same protocol, was also recruited between April 2018 and October 2022. These children were invited through nursery schools or recruited when referred to the ophthalmological department for other reasons.

2.1 | Ophthalmological examinations

Manifest or intermittent strabismus and eye motility were noted. Refraction was measured in cycloplegia after instillation of eye drops, including cyclopentolate 1.5% and phenylephrine 0.85%. The spherical component and astigmatism were noted, and the spherical equivalent was calculated. Hyperopia was considered significant if equal to or greater than 2.00 dioptre (D) and myopia if equal to or lower than 0.50 D (Grönlund et al., 2006). Astigmatism and anisometropia were considered significant if equal to or greater than 1.00 D.

The study was approved by the Ethical Review Board of Uppsala (2017/452) and the Swedish Ethical Review Authority (2019–05851, 2022–01851-02), Sweden, and was performed in accordance with the Declaration of Helsinki.

2.2 | Statistical methods

Descriptive statistics were analysed using SPSS version 28 (IBM Corp., Armonk, NY, USA). Further statistical analysis was performed using SAS 9.4 (SAS Institute Inc., Cary, NC). Due to the small number of children with lambdoid craniosynostosis ($n=2$), this type was excluded from the statistical analysis.

The study group and control group were compared with independent t-test. Regarding the study group, in order to assess the effect of type of craniosynostosis on the outcomes, logistic (proportional odds) ordinal regression models were fitted for ordinal outcomes and exact logistic regression models were fitted for binary outcomes (yes/no). The models were adjusted for gender. For binary outcomes, McNemar's tests were used to evaluate the agreement between preoperative and postoperative results in the study group.

Due to the explanatory nature of the study, no adjustments were performed for multiplicity; thus, all *p*-values should be interpreted with that in mind. A *p*-value of <0.05 was regarded as statistically significant.

3 | RESULTS

Demographics of the total study group are given in [Table 1](#). Mean/median age at examination was 5.12/5.05 years (range 4.54–6.09 years) in the study group and 5.32/5.25 years (range 4.84–5.95 years) in the control group.

The refractive outcomes are presented in [Table 2](#).

3.1 | Sagittal craniosynostosis

Of 58 children with sagittal craniosynostosis, refraction was assessed in 58 right eyes (REs) and 57 left eyes (LEs). The mean/median spherical equivalent (SE) was +1.44/+1.50D, (range –0.125 to +3.50) in REs and +1.46/+1.50D (range –0.625 to +3.50D) in LEs.

Refractive data are presented in [Tables 2 and 3](#).

One of the children with sagittal craniosynostosis was found to have intermittent exotropia and inferior oblique overaction at the follow-up examination at 5 years of age.

3.2 | Metopic craniosynostosis

In the metopic craniosynostosis group, refraction was assessed in all 15 REs and LEs. The mean/median SE was +2.21/+1.88D (range +0.88 to +5.50D) in the REs and +2.18/+2.00D (range +0.75 to +5.75D) in the LEs, respectively. Data are presented in [Tables 2 and 3](#).

Orthoptic examination was conducted in 14 children; none of them had strabismus.

3.3 | Unicoronal craniosynostosis

Of the 14 children with unicoronal craniosynostosis, refraction was assessed in 13 REs and LEs. Data are presented in [Tables 2 and 3](#). The mean/median SE was +2.10/+1.75D (range +0.63 to +4.13D) in the REs and +1.73/+2.25D (range –0.25 to +5.50D) in the LEs.

Aniso-astigmatism of 1D or more was found in 6/13 children; in 5/6 children, the greater degree was detected on the contralateral eye to the fused suture.

Strabismus was observed in 10/14 children (71%). Five new cases of strabismus were found at the 5-year follow-up. The main type was exotropia with a vertical component ([Figure 1](#)). Motility examination revealed overaction in adduction and hypertropia in 6/14 cases (43%), consistent with a pseudo-superior oblique palsy predominantly ipsilateral to the fused suture. Monocular elevation deficiency and hypotropia were noted in two cases: in one case, ipsilateral, and in another, contralateral to the fused suture.

3.4 | Lambdoid craniosynostosis

Refraction and orthoptic examination were conducted on the two children with lambdoid craniosynostosis. Data are presented in [Tables 2 and 3](#). The mean/median SE was +2.13/+2.13D (range +1.38 to +2.86D) in the REs and +2.25/+2.25D (range +1.38 to +3.88D) in the LEs.

Strabismus or motility disorders were not found.

3.5 | Control group

Refraction and orthoptic examination were conducted on 32 children. The mean/median SE was +1.36/+1.25D (range +0.25 to +4.00D) in the REs and +1.48/+1.25D (range +0.25 to +4.25D) in the LEs. Data are presented in [Tables 2 and 3](#).

No child had strabismus.

3.6 | Comparison of different types of craniosynostosis at five-year follow-up

When comparing refraction, there was a difference regarding the spherical component in REs and LEs between the different types of craniosynostosis ($p=0.01$ and $p=0.005$, respectively), mainly due to higher values of hypermetropia in the metopic and unicoronal craniosynostosis groups compared to the sagittal group; see [Table 2](#). There was also a difference regarding the prevalence of hypermetropia ≥ 2 D (REs $p=0.03$ and LEs $p=0.01$); see [Table 3](#). Mean values of astigmatism differed statistically

TABLE 1 Number and fraction (%) of children included in the study group at the 5-year follow-up, together with the control group, and age at surgery in the study group.

	Number (%)	Sex F:M	Age at surgery (months) ^a
Total group craniosynostosis	89	26:63	7.39 (3.2–42.6)
Sagittal	58 (65.2%)	12:47	4.9 (3.2–32.1)
Metopic	15 (16.9%)	4:11	8.2 (6.6–11.2)
Unicoronal	14 (15.7%)	9:5	10.5 (7.8–42.6)
Lambdoid	2 (2.2%)	1:1	26.0 (22.8–29.2)
Control group	32	15:17	–

Abbreviations: F, female; M, male.

^aMedian values and ranges are given for ages.

TABLE 2 Mean/median values (range) of spherical component and astigmatism at 5 years of age in 88 REs and 87 LEs, divided by type of craniosynostosis, as well as in 32 REs and LEs eyes in the control group.

	Refraction spherical RE	Refraction spherical LE	Refraction astigmatism RE	Refraction astigmatism LE
Total group craniosynostosis	+1.89/+1.75D (0 to +6.00)	+1.99/+1.75D (-0.50 to +6.25)	-0.34/-0.25D (-2.75 to 0)	-0.49/-0.25D (-3.75 to 0)
Sagittal	+1.50/+1.50D (0 to +4.50)	+1.62/+1.50D (-0.50 to +4.50)	-0.28/-0.25D (-2.75 to 0)	-0.33/-0.25D (-3.00 to 0)
Metopic	+2.45/+2.25D (+1.00 to +6.00)	+2.43/+2.00D (+1.00 to +6.25)	-0.48/-0.50D (-1.00 to 0)	-0.52/-0.50D (-2.75 to 0)
Unicoronal	+2.31/+2.00D (1 to +4.50)	+2.94/+2.50D (+1.25 to +6.00)	-0.42/-0.50D (-1.25 to 0)	-1.23/-1.00D (-3.75 to 0)
Lambdoid	+1.86/+1.75D (0 to +4.00)	+2.75/+2.75D (+1.50 to +4.00)	-0.25/-0.25D (-0.25)	-0.25/-0.25D (-0.25)
Control group	+1.52/+1.37D (+0.5 to +4.25)	+1.63/+1.37D (+0.25 to +4.5)	-0.33/-0.25D (-1.5 to 0)	-0.31/-0.25D (-1.5 to 0)

Abbreviations: D, dioptre; LEs, left eyes; REs, right eyes.

TABLE 3 Prevalence, number and fraction (%), of spherical component $\geq 2D$ and astigmatism $\geq 1D$ at 5 years of age in 88 REs and 87 LEs of the study group divided by type of craniosynostosis, and in 32 REs and LEs in the control group, as well as anisometropia of spherical component and astigmatism $\geq 1D$ in the study group and the control group.

	Refraction spherical $\geq 2D$ RE	Refraction spherical $\geq 2D$ LE	Astigmatism $\geq 1D$ RE	Astigmatism $\geq 1D$ LE	Anisometropia spherical $\geq 1D$	Anisometropia astigmatism $\geq 1D$
Total group craniosynostosis	37/88 (42.0%)	37/87 (42.5%)	7/88 (8.0%)	13/87 (15.3%)	4/87 (4.6%)	9/87 (10.3%)
Sagittal	18/58 (31.0%)	17/57 (29.8%)	3/58 (5.2%)	4/57 (7%)	0/57	2/57 (3.5%)
Metopic	9/15 (60.0%)	9/15 (60.0%)	3/15 (20%)	2/15 (13.3%)	1/15 (6.7%)	1/15 (6.7%)
Unicoronal	9/13 (69.2%)	10/13 (76.9%)	1/13 (7.7%)	7/13 (53.8%)	3/13 (23.1%)	6/13 (46.2%)
Lambdoid	1/2 (50.0%)	1/2 (50.0%)	0/2	0/2	0/2	0/2
Controls	10/32 (45%)	12/32 (37%)	2/32 (6.2%)	1/32 (3.1%)	1/32 (3.1%)	1/32 (3.1%)

Abbreviations: D, dioptre; REs, right eyes; LEs, left eyes.

between the groups (REs $p=0.006$ and LEs $p<0.001$); see Table 2. However, the prevalence of astigmatism ≥ 1 D differed only in LEs ($p=0.002$); see Table 3. Regarding anisometropia of spherical component ≥ 1 D ($p=0.02$) and anisometropia of astigmatism ≥ 1 D ($p=0.001$), the difference was due to the higher values in the unicoronal craniosynostosis group (Table 3). Regarding strabismus, there was a difference among subtypes of craniosynostosis ($p<0.001$), with the unicoronal synostosis having a higher prevalence (Table 4).

3.7 | Comparison between the control group and study group at 5 years

Comparing the control group and study group adjusted for gender, there was a difference regarding the refractive values between the groups; see Tables 2 and 3. The differences were caused by the higher values of hypermetropia (REs $p=0.003$, LEs $p<0.001$) in the metopic and unicoronal craniosynostosis groups compared to the controls. The differences between the groups regarding astigmatism in LEs ($p<0.001$), anisometropia of spherical component ($p=0.001$) and anisometropia of astigmatism ($p=0.008$) were due to the higher values in the unicoronal group. The children with sagittal craniosynostosis did not have a higher risk for a refractive error compared to the children without non-syndromic craniosynostosis.

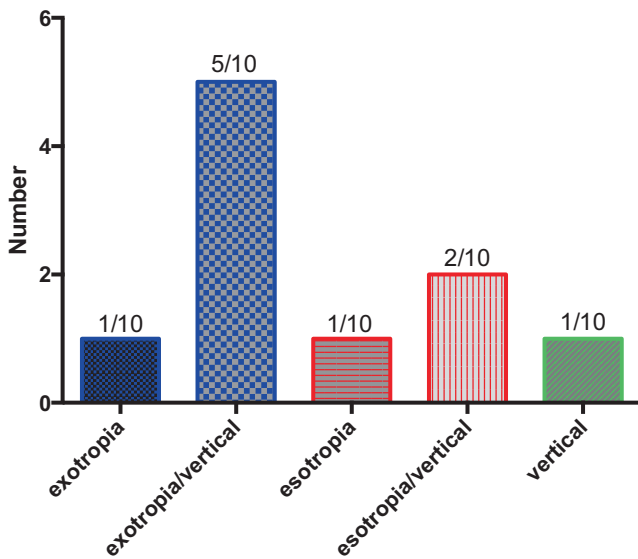


FIGURE 1 Prevalence of different types of strabismus in unicoronal craniosynostosis at 5-year follow-up.

3.8 | Development of refraction over time in different types of craniosynostosis

Regarding refractive development of mean/median values over time, see Figure 2a–f. Spherical component ≥ 2 D changed statistically significantly over time in both eyes ($p=0.0008$ and $p=0.0002$, respectively). Similar results were found for astigmatism ≥ 1 D ($p=0.0002$ for REs and $p=0.006$ for LEs). However, anisometropia of spherical component ≥ 1 D and anisometropia of astigmatism ≥ 1 D did not change statistically over time.

3.9 | Development of strabismus over time in different types of craniosynostosis

Three children with sagittal synostosis, all under 3 months of age, were found to have strabismus preoperatively (exotropia), but in all cases, the exotropia disappeared at the first postoperative examination. Two of them were lost to the 5-year follow-up. One new case of intermittent exotropia was found at the 5-year follow-up.

In the metopic craniosynostosis group, no child had strabismus preoperatively, but one was found to have esotropia at the first postoperative examination. This child failed to cooperate with proper orthoptic examination; therefore, strabismus could not be confirmed at the 5-year follow-up. No new cases were found.

Regarding strabismus in the unicoronal craniosynostosis group, three children (two with exotropia and one with esotropia) had strabismus at all three examinations. Two new cases (one exotropia and one esotropia) were found at 6–12 months postoperatively, which remained at the 5-year follow-up. The same children also developed vertical deviation. One child with intermittent exotropia both preoperatively and 6 months postoperatively was lost to follow-up. Five new cases of horizontal and vertical deviation combined were found at 5 years of age.

The development of strabismus over time in our cohort of children aged 5 years old is presented in Table 4.

4 | DISCUSSION

In this study of 89 children, aged 5 years old, who underwent operations for various types of single-suture craniosynostosis, the highest rates of ophthalmological dysfunctions such as astigmatism, anisometropia and strabismus were found in those operated for unilateral coronal craniosynostosis. Children operated for metopic

TABLE 4 Prevalence of strabismus over time in children aged 5 years old who were examined in at least two of three occasions (preoperatively, 6–12 months postoperatively and 5 years of age), divided by type of craniosynostosis.

	Strabismus preoperatively Number and fraction (%)	Strabismus 6–12 months postoperatively Number and fraction (%)	Strabismus at 5-year follow-up Number and fraction (%)
Total	4/81 (5.0%)	6/76 (8.0%)	11/88 (12.5%)
Sagittal	1/52 (2.0%)	0/50	1/58 (1.75%)
Metopic	0/15	1/13 (8.0%)	0/14
Unicoronal	3/14 (21.4%)	5/13 (38.5%)	10/14 (71.4%)
Lambdoid	0/1	0/0	0/2

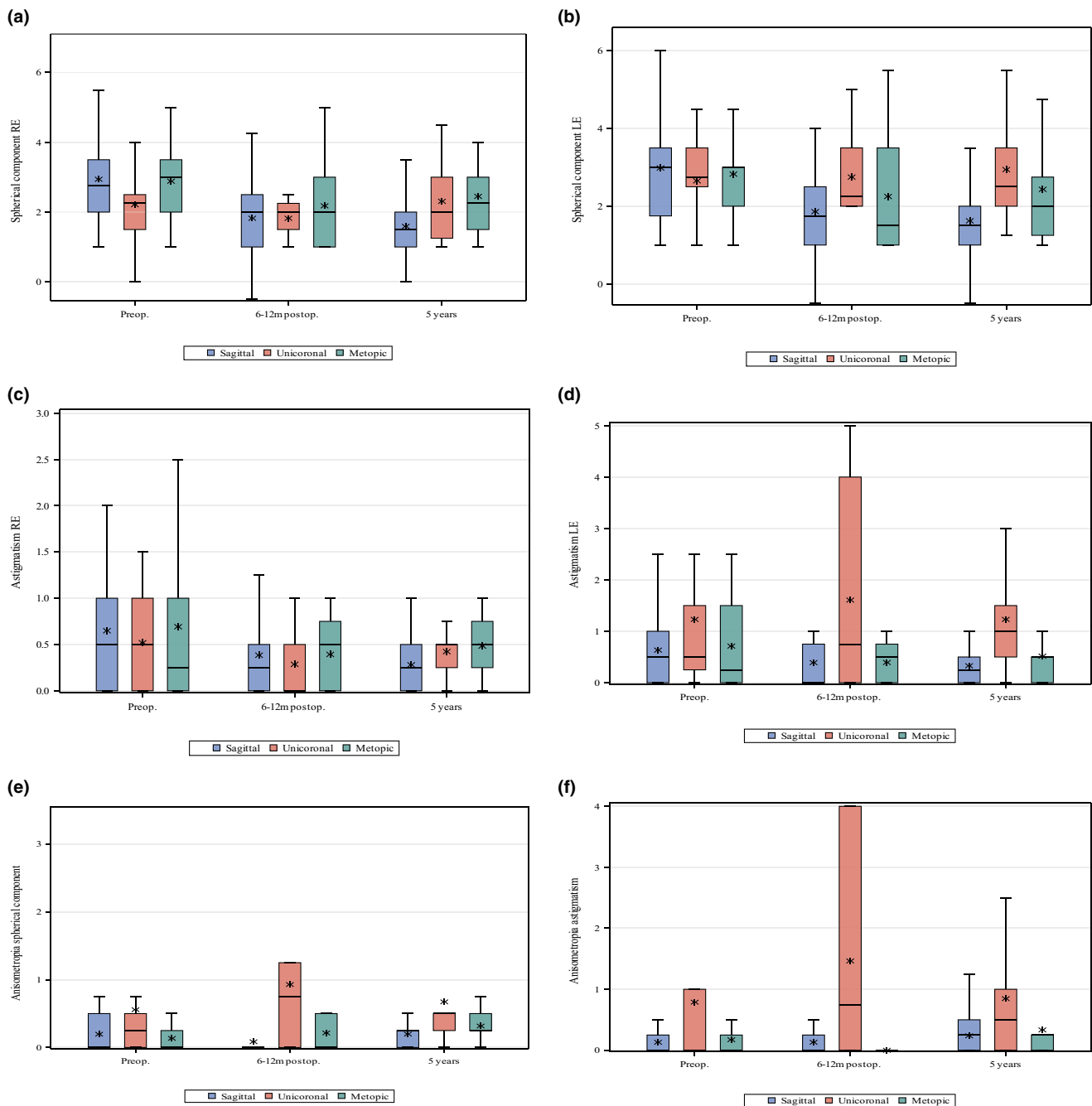


FIGURE 2 Boxplots for preoperative and postoperative results for spherical component REs (a) and LEs (b), as well as astigmatism for REs (c) and LEs (d) and anisometropia spherical component (e) and astigmatism (f) visualised by the craniosynostosis type. The asterisk indicates mean values.

craniosynostosis also had a high rate of hypermetropia. Ophthalmological dysfunctions were rare in children who underwent an operation for sagittal craniosynostosis.

Previously, among the various types of non-syndromic craniosynostosis, focus has mainly been on the effects of metopic and unilateral coronal craniosynostosis. Less research has been reported about sagittal craniosynostosis. Moreover, there is a paucity of studies that compare the ophthalmological outcomes between the different types of non-syndromic craniosynostosis or that systematically follow up on the children to evaluate the longitudinal effects on preschool age. The present study was the first to analyse the ophthalmological findings in relation to the different types of non-syndromic craniosynostosis before and after craniofacial surgery

and to evaluate the long-term effects. Vasco et al. (2008) followed 129 children, and Chieffo et al. (2020) followed 142 children, however only up to 1 year postoperatively. Gupta et al. (2003) retrospectively reviewed a cohort of 45 children at different ages, from birth to 14 years, including all subtypes of non-syndromic craniosynostosis, and reported a higher prevalence of astigmatism and strabismus (exotropia) than in the general population. In a cohort of 37 craniosynostosis patients, 1 month old to 14 years of age, including both syndromic and non-syndromic forms, Rafique Ali et al. (2022) found that non-syndromic craniosynostosis patients are also at risk of developing ocular manifestations, although the majority of their patients are children with unilateral coronal craniosynostosis (6/8).

In this study, we found a significant difference in the refractive values between the different groups of non-syndromic craniosynostosis. A high rate of hypermetropia in the metopic group was found. This was in agreement with the results by Macintosh et al. (2011), who reported high rates of hypermetropia but low rates of astigmatism. Other studies have reported a high prevalence of astigmatism (Denis et al., 1996; Nguyen et al., 2016). In the present study, children with metopic craniosynostosis had higher rates of astigmatism compared to the sagittal group. The discrepancy between the different studies might be explained by the varying age range. It is known that the refraction in a child changes over time, with neonates usually being more hypermetropic in combination with astigmatism, which decreases with the child's growth (Abrahamsson et al., 1988; Mayer et al., 2001).

Furthermore, this study revealed higher rates of hypermetropic anisometropia and astigmatism in the unilateral coronal craniosynostosis group, mainly on the side contralateral to the fused suture. The latter was in agreement with other studies in the literature (Macintosh et al., 2007; Levy et al., 2007; Luo et al., 2020; Touzé et al., 2022). It is hypothesised that the orbital dysmorphology caused by the compensatory growth contralateral to the fused suture in the unicoronal synostosis, which persists despite surgical treatment (Lif et al., 2023), has an impact on the corneal curvature, causing astigmatism. Furthermore, fronto-orbital advancement (FOA), which is considered to be a gold standard surgery for unicoronal craniosynostosis, improves the skull asymmetry; however, it fails to reduce the astigmatism and anisometropia (Elhusseiny et al., 2021; Gencarelli et al., 2016; Song et al., 2016; Tarczy-Hornoch et al., 2008).

Regarding the refractive values over time, high hypermetropia and astigmatism were found in all types of craniosynostosis preoperatively and decreased in the sagittal group like in normally developing children (Abrahamsson et al., 1988; Mayer et al., 2001). On the contrary, high values remained throughout the study period in the unicoronal craniosynostosis group, particularly on the contralateral side to the fused suture. In the metopic group, hypermetropia remained on both eyes. Although astigmatism decreased, relatively high values remained in the REs. Vasco et al. (2008) did not find any changes in the refractive values before and after surgery; however, they followed the children only up to 1 year postoperatively. Chieffo et al. (2020) did not report on refraction.

In the present study, the children with non-syndromic craniosynostosis had higher values and a higher prevalence of refractive errors compared to the control group at 5 years, except for the sagittal subgroup, in which the values did not differ. Our control group was fairly small; however, the prevalence of refractive errors in this group was rather similar to the findings in other studies of normally developing children of the same age (Grönlund et al., 2006; Hellgren et al., 2016).

Regarding strabismus, the prevalence in our cohort was higher than in the control group and in other studies of the general population both at 5-year follow-up and longitudinally (Grönlund et al., 2006; Hashemi

et al., 2019). This was caused by the high prevalence in patients with unicoronal craniosynostosis. Ten of 14 children with unicoronal craniosynostosis had strabismus, with the majority having exotropia with vertical component (Figure 1). In 7 children, the strabismus developed postoperatively, of whom 5 had new onsets between the first postoperative eye examination and 5 years of age. In agreement with our results, Samra et al. (2015) reported a new onset of strabismus in 23/50 patients and Yu et al. (2020) in 3/19. Lee et al. (2008) and Gupta et al. (2003) reported persistence of the high preoperative strabismus rates. High rates of horizontal strabismus and vertical deviations in children operated with fronto-orbital advancement were also reported in numerous other studies (Denis, Genitori, Bolufer, et al., 1994; Elhusseiny et al., 2021; Luo et al., 2020; Macintosh et al., 2007; Rafique Ali et al., 2022; Song et al., 2016; Touzé et al., 2022). The most common type of vertical strabismus in our study, as well as in those above, appeared to be specifically hypertropia of the ipsilateral eye to the fused suture. Its pathogenesis is speculated to be related to the orbital dysmorphology seen in unicoronal craniosynostosis, specifically orbital dystopia and malposition of the trochlea, which leads to oculomotor imbalance. It could also be correlated to the effects of the fronto-orbital technique itself. In a meta-analysis and systematic review of studies regarding the ophthalmological outcome following the fronto-orbital advancement for unicoronal craniosynostosis, Gencarelli et al. (2016) concluded that this technique did not appear to fundamentally reduce the rates of strabismus. In addition, it may increase the risk of iatrogenic strabismus through the periorbital dissection and remodelling it entails, resulting in repositioning of the trochlea and oblique muscle insertions and causing motility abnormalities that simulate a trochlear nerve palsy.

No child with metopic craniosynostosis had strabismus in our group, and only one child with sagittal craniosynostosis appeared to have intermittent exotropia at the follow-up examination at 5 years of age. The low prevalence was in agreement with other studies in the literature (Denis, Genitori, Bardot, et al., 1994; Gupta et al., 2003). However, other authors have reported a higher prevalence of strabismus compared to the general population (Macintosh et al., 2011; Nguyen et al., 2016).

The strength of this study was the prospective design, with almost all children examined at our department by a multidisciplinary team following a study protocol. The examination was performed by an experienced orthoptist and paediatric ophthalmologist in order to obtain reliable data. Furthermore, it was a follow-up study of children who had undergone an operation for various types of non-syndromic craniosynostosis at our centre. These children were previously also ophthalmologically examined preoperatively and 6–12 months after the operation. This allowed us to evaluate the longitudinal ophthalmological effects and systematically compare the outcomes between the different types. This has not previously been reported in the literature. One limitation was that only 89 of the original cohort of 122 children were examined at the 5-year follow-up. This was due to the prospective nature

of the study, as not all children had reached this age during the time the study was conducted. Another limitation was the lack of a larger control group and that some of the children were recruited at the ophthalmological department, which could be a bias. Nonetheless, we refer to previous studies on the rates of refractive errors and strabismus in the general population.

In conclusion, this study confirmed our previous results that children with sagittal craniosynostosis did not have a risk of developing oculomotor disorders and refractive errors compared to other subtypes. Ocular manifestations such as strabismus, particularly vertical deviation and astigmatism, especially on the contralateral side, were highly prevalent in unicoronal craniosynostosis; furthermore, single-suture metopic craniosynostosis was related to higher rates of hypermetropia. The role of a paediatric ophthalmologist is therefore important for the early detection and treatment of any ophthalmic disorder. Furthermore, the screening and follow-up protocols need to be tailored with regard to the type of craniosynostosis. An ongoing study regarding visual outcome in the same cohort will further elucidate the long-term ophthalmological effects and form the basis for the refinement and development of screening protocols in children with non-syndromic craniosynostosis.

ACKNOWLEDGEMENTS

We thank biostatistician Tatevik Ghukasyan Latic, for the valuable help with the statistics; and orthoptists Jenny Bjuhr, Sofia Ferngren and Jonina Hreinsdottir, for their help with orthoptic examinations.

The study was funded by Ögonfonden and Stiftelsen Kronprinsessan Margaretas Arbetsnämnd för synskadade. The funders had no involvement in the study design; in the collection, analysis and interpretation of the data; in the writing of the report; and in the decision to submit the paper for publication.

CONFLICT OF INTEREST STATEMENT

The authors declare they have no conflict of interests.

ORCID

Evangelia Ntola  <https://orcid.org/0009-0007-6444-2034>

Daniel Nowinski  <https://orcid.org/0000-0002-8371-9314>

Gerd Holmström  <https://orcid.org/0000-0002-5600-7186>

Eva Larsson  <https://orcid.org/0000-0001-9674-0094>

REFERENCES

- Abrahamsson, M., Fabian, G. & Sjöstrand, J. (1988) Changes in astigmatism between the ages of 1 and 4 years: a longitudinal study. *The British Journal of Ophthalmology*, 72(2), 145–149.
- Chieffo, D.P.R., Arcangeli, V., Bianchi, F., Salerni, A., Massimi, L., Frassanito, P. et al. (2020) Single-suture craniosynostosis: is there a correlation between preoperative ophthalmological, neuroradiological, and neurocognitive findings? *Child's Nervous System*, 36, 1481–1488.
- Chung, S.A., Yun, I.S., Moon, J.W. & Lee, J.B. (2015) Ophthalmic findings in children with nonsyndromic craniosynostosis treated by expansion cranioplasty. *The Journal of Craniofacial Surgery*, 26(1), 79–83.
- Denis, D., Genitori, L., Bardot, J., Saracco, J.B., Choux, M. & Maumenee, I.H. (1994) Ocular findings in trigonocephaly. *Graefes' Archive for Clinical and Experimental Ophthalmology*, 32(12), 728–733.
- Denis, D., Genitori, L., Bolufer, A., Lena, G., Saracco, J.B. & Choux, M. (1994) Refractive error and ocular motility in plagiocephaly. *Child's Nervous System*, 10(4), 210–216.
- Denis, D., Genitori, L., Conrath, J., Lena, G. & Choux, M. (1996) Ocular findings in children operated on for plagiocephaly and trigonocephaly. *Child's Nervous System*, 12(11), 683–689.
- Elhusseiny, A.M., MacKinnon, S., Zurakowski, D., Huynh, E. & Dagi, L.R. (2021) Long-term ophthalmic outcomes in 120 children with unilateral coronal synostosis: a 20-year retrospective analysis. *Journal of AAPOS*, 25(2), 76.e1–76.e5.
- Gencarelli, J.R., Murphy, A., Samargandi, O.A. & Bezuhly, M. (2016) Ophthalmologic outcomes following fronto-orbital advancement for unicoronal craniosynostosis. *The Journal of Craniofacial Surgery*, 27, 1629–1635.
- Governale, L.S. (2015) Craniosynostosis. *Pediatric Neurology*, 53(5), 394–401.
- Grönlund, M.A., Andersson, S., Aring, E., Hård, A.L. & Hellström, A. (2006) Ophthalmological findings in a sample of Swedish children aged 4–15 years. *Acta Ophthalmologica Scandinavica*, 84(2), 169–176.
- Gupta, P.C., Foster, J., Crowe, S., Papay, F.A., Luciano, M. & Traboulsi, E.I. (2003) Ophthalmologic findings in patients with nonsyndromic plagiocephaly. *The Journal of Craniofacial Surgery*, 14(4), 529–532.
- Hashemi, H., Pakzad, R., Heydarian, S., Yekta, A., Aghamirsalim, M., Shokrollahzadeh, F. et al. (2019) Global and regional prevalence of strabismus: a comprehensive systematic review and meta-analysis. *Strabismus*, 27, 54–65.
- Hellgren, K.M., Tornqvist, K., Jakobsson, P.G., Lundgren, P., Carlsson, B., Källén, K. et al. (2016) Ophthalmologic Outcome of Extremely Preterm Infants at 6.5 Years of Age: Ophthalmologic Outcome of Extremely Preterm Infants at 6.5 Years of Age: Extremely Preterm Infants in Sweden Study (EXPRESS). *JAMA Ophthalmology*, 134(5), 555–562.
- Hinds, A.M., Thompson, D.A., Rufai, S.R., Weston, K., Schwiebert, K., Panteli, V. et al. (2022) Visual outcomes in children with syndromic craniosynostosis: a review of 165 cases. *Eye (London, England)*, 36(5), 1005–1011.
- Khan, S.H., Nischal, K.K., Dean, F., Hayward, R.D. & Walker, J. (2003) Visual outcomes and amblyogenic risk factors in craniosynostotic syndromes: a review of 141 cases. *The British Journal of Ophthalmology*, 87(8), 999–1003.
- Lee, S.J., Dondy, J., Greensmith, A., Holmes, A.D. & Meara, J.G. (2008) The effect of fronto-orbital advancement on strabismus in children with unicoronal synostosis. *Annals of Plastic Surgery*, 61, 178–180.
- Levy, R.L., Rogers, G.F., Mulliken, J.B., Proctor, M.R. & Dagi, L.R. (2007) Astigmatism in unilateral coronal synostosis: incidence and laterality. *Journal of AAPOS*, 11(4), 367–372.
- Lif, H.M., Nysjö, J.E., Vegelius, J.R., Unander-Scharin, J., Enblad, P. & Nowinski, D.J. (2023) Persistent discrepancies in orbital morphology after surgical treatment of unicoronal craniosynostosis: a critical image-based analysis. *Journal of Neurosurgery Pediatrics*, 10, 1–10.
- Luo, W.T., Chen, X., Zhang, Y.D., Liu, Q.Y. & Qiao, T. (2020) Ophthalmological outcomes of unilateral coronal synostosis in young children. *BMC Ophthalmology*, 20(1), 318.
- Macintosh, C., Wall, S. & Leach, C. (2007) Strabismus in unicoronal synostosis: ipsilateral or contralateral? *The Journal of Craniofacial Surgery*, 18(3), 465–469.
- Macintosh, C., Wells, R., Johnson, D. & Wall, S. (2011) What are the effects of metopic synostosis on visual function? *The Journal of Craniofacial Surgery*, 22(4), 1280–1283.
- Mayer, D.L., Hansen, R.M., Moore, B.D., Kim, S. & Fulton, A.B. (2001) Cycloplegic refractions in healthy children aged 1 through 48 months. *Archives of Ophthalmology*, 119(11), 1625–1628.
- Nguyen, T.B., Shock, L.A., Missoi, T.G. & Muzaffar, A.R. (2016) Incidence of amblyopia and its risk factors in children with isolated metopic craniosynostosis. *The Cleft Palate-Craniofacial Journal*, 53(1), e14–e17.

- Ntoula, E., Nowinski, D., Holmstrom, G. & Larsson, E. (2021) Ophthalmological findings in children with non-syndromic craniosynostosis: preoperatively and postoperatively up to 12 months after surgery. *BMJ Open Ophthalmology*, 6, e000677.
- Rafique Ali, A.A., Ismail, F., May May, C., Mohd Abdullah, A.A., Khaliddin, N., Hariri, F. et al. (2022) Ophthalmic features of craniosynostosis: a Malaysian experience. *European Journal of Ophthalmology*, 32(3), 1417–1423.
- Roider, L., Ungerer, G., Shock, L., Aldridge, K., Al-Samarraie, M., Tanaka, T. et al. (2021) Increased incidence of ophthalmologic findings in children with concurrent isolated nonsyndromic metopic suture abnormalities and deformational cranial vault asymmetry. *The Cleft Palate-Craniofacial Journal*, 58(4), 497–504.
- Samra, F., Paliga, J.T., Tahiri, Y., Whitaker, L.A., Bartlett, S.P., Forbes, B.J. et al. (2015) The prevalence of strabismus in unilateral coronal synostosis. *Child's Nervous System*, 31, 589–596.
- Song, H.B., Yang, H.K., Baek, R.M., Hwang, J.M., Kim, N., Wang, K.C. et al. (2016) Effect of fronto-orbital advancement on astigmatism in patients with anterior plagiocephaly. *Journal of Cranio-Maxillo-Facial Surgery*, 44(10), 1504–1507.
- Tarczy-Hornoch, K., Smith, B. & Urata, M. (2008) Amblyogenic anisometropia in the contralateral eye in unicoronal craniosynostosis. *Journal of AAPOS*, 12(5), 471–476.
- Tarnow, P., Kölby, L., Maltese, G., Söfteland, M.B., Lewén, A., Nilsson, P. et al. (2022) Incidence of non-syndromic and syndromic craniosynostosis in Sweden. *Craniofacial surgery*, 33(5), 1517–1520.
- Tay, T., Martin, F., Rowe, N., Johnson, K., Poole, M., Tan, K. et al. (2006) Prevalence and causes of visual impairment in craniosynostotic syndromes. *Clinical & Experimental Ophthalmology*, 34(5), 434–440.
- Touzé, R., Bremond-Gignac, D. & Robert, M.P. (2019) Ophthalmological management in craniosynostosis. *Neurochirurgie*, 65(5), 310–317.
- Touzé, R., Paternoster, G., Arnaud, E., Khonsari, R.H., James, S., Bremond-Gignac, D. et al. (2022) Ophthalmological findings in children with unicoronal craniosynostosis. *European Journal of Ophthalmology*, 32(6), 3274–3280.
- Vasco, G., Baranello, G., Ricci, D., Salerni, A., Tamburrini, G., Amante, R. et al. (2008) Longitudinal assessment of visual development in non-syndromic craniosynostosis: a 1-year pre- and post-surgical study. *Archives of Disease in Childhood*, 93, 932–935.
- Yu, J.W., Xu, W., Wink, J.D., Wes, A.M., Bartlett, S.P. & Taylor, J.A. (2020) Strabismus in Unicoronal craniosynostosis: effect of orbital dysmorphology and Fronto-orbital advancement and remodeling. *Plastic and Reconstructive Surgery*, 145(2), 382e–390e.

How to cite this article: Ntoula, E., Nowinski, D., Holmström, G. & Larsson, E. (2023) Strabismus and refraction in non-syndromic craniosynostosis – A longitudinal study up to 5 years of age. *Acta Ophthalmologica*, 00, 1–9. Available from: <https://doi.org/10.1111/aos.16605>