



## Research article

# Effect of needle size on outcomes of vacuum-assisted excision of breast lesions. A randomized controlled trial

Athanasios Zouzos<sup>a,b,\*</sup>, Irma Fredriksson<sup>c,d</sup>, Andreas Karakatsanis<sup>e,f</sup>, Iliana Aristokleous<sup>e,f</sup>, Theodoros Foukakis<sup>b,d</sup>, Fredrik Strand<sup>a,b</sup>

<sup>a</sup> Department of Radiology, Karolinska University Hospital, Stockholm, Sweden

<sup>b</sup> Department of Oncology and Pathology, Karolinska Institutet, Stockholm, Sweden

<sup>c</sup> Department of Molecular Medicine and Surgery, Karolinska Institutet, Stockholm, Sweden

<sup>d</sup> Department of Breast, Endocrine Tumors and Sarcoma, Karolinska Comprehensive Cancer Center, Karolinska University Hospital, Stockholm, Sweden

<sup>e</sup> Department of Surgical Sciences, Uppsala University, Uppsala, Sweden

<sup>f</sup> Section for Breast Surgery, Department of Surgery, Uppsala University Hospital, Uppsala, Sweden



## ARTICLE INFO

## Keywords:

Breast  
Mammography  
Needle size  
Ultrasound  
Vacuum-assisted excision

## ABSTRACT

**Background:** Utilizing a larger needle-size instead of a smaller one in vacuum-assisted excision of breast lesions might enhance the effectiveness of the method. We conducted a clinical trial to investigate the effects of needle size 7G compared to 10G regarding excision completeness and procedural efficiency.

**Materials and methods:** In this prospective, single-blinded, randomized clinical trial, the patients were enrolled between November 2019 and August 2022. Follow-up examinations were performed at 6 and 24 months after the procedure. In total, 208 patients were screened and enrolled, and following withdrawal of consent, the trial population comprised 194 patients. All patients with ultrasound-visible lesions of <30 mm in size and biopsy confirmation corresponding to a B2 or B3 lesion were included in the study. Additionally, patients with BI-RADS 3 and 4a microcalcifications measuring <15 mm were also eligible. Eighty-five percent of the patients attended the 6-month follow-up, and 65 % attended the 24-month follow-up.

**Results:** There were no significant difference between the two randomization arms in terms of age, and lesion size. The mean procedure time was 7.7 min and 8.5 min for 7G and 10G needle size, respectively ( $=0.126$ ). Of the 164 patients who attended the 6-month follow-up, no remaining lesions were found in 90 % and 81.5 % ( $p = 0.109$ ) patients for 7G and 10G needle size respectively. Thirty percent (6/20) of the patients with microcalcifications excised stereotactically, guided by mammography, had a residual lesion compared to 2.5 % (1/42) of the patients with intraductal lesions excised under ultrasound guidance.

**Conclusions:** Using a 10G compared to a 7G needle size resulted in no difference in procedure time or excision completeness. Among the analyzed parameters, only a larger lesion size was consistently associated with a longer procedure time and a higher risk of incomplete excision.

## 1. Introduction

Vacuum-assisted biopsy (VAB) for breast lesions has gradually evolved from a diagnostic modality to a therapeutic approach (i.e., vacuum-assisted excision [VAE]) for the removal of small lesions that are deemed benign but have uncertain malignant potential in the histopathological analysis of an initial biopsy [1–5]. Following core-biopsy, lesions categorized as B3 (breast lesions with uncertain malignant potential), according to European Guidelines [6,7], can have heterogeneous radiologic features. These features are categorized according to

the Breast Imaging Reporting and Data System (BI-RADS), [8] ranging from BI-RADS 2 to BI-RADS 4a. VAE can be performed guided by stereotactic mammography [9–12], ultrasonography [11–21] or even magnetic resonance [22,23] with needle sizes varying from 7G (3.8 mm) [24] to 11G (2.4 mm) [9].

The literature, reports complete excision in 72 %–99 % of cases [10,14,17–20,25]. Notably, complete excision has mostly been evaluated through visual and radiological assessments of the absence of tumor signs in the excision area directly following the procedure. In contrast to surgical lesion removal, the simple implementation of VAE does not

\* Corresponding author at: Department of Radiology, Karolinska University Hospital, SE-171 76 Stockholm, Sweden.

E-mail address: [athanasios.zouzos@ki.se](mailto:athanasios.zouzos@ki.se) (A. Zouzos).

allow the direct estimation of completeness by histopathology because of the fragmentation of the tissue sample.

Lesion size, morphology, and the distance between the lesion and sensitive structures have previously been identified as predictors of the efficacy of VAE [26,27]. Van de Voort et al. [28] concluded that VAE was effective for excising lesions up to 50 mm in size, whereas others have recommended VAE for excising lesions up to 30 mm in size [10,16,29]. Needle size essentially plays a key role in excisional performance and diagnosis, with data showing the advantages of bigger needles [27,30,31]. Only two studies [18,24] utilizing the 7G needle size have been published with small study populations. Time is another important parameter, because procedural efficiency is one of the main advantages of excisional surgical biopsies. Procedure time has been

reported in a few studies [13,16,18,31] indicating that it may be influenced by the doctor's experience, method used, needle size, tumor size, lesion location and morphology, and surrounding tissue.

To the best of our knowledge, this is the first randomized trial to address the issue of 7G needle size in relation to the effectiveness of VAE. The main objective of our study is to better understand how needle size effects complete excision and procedure time by comparing two different needle sizes (7G and 10G).

### CONSORT flow diagram

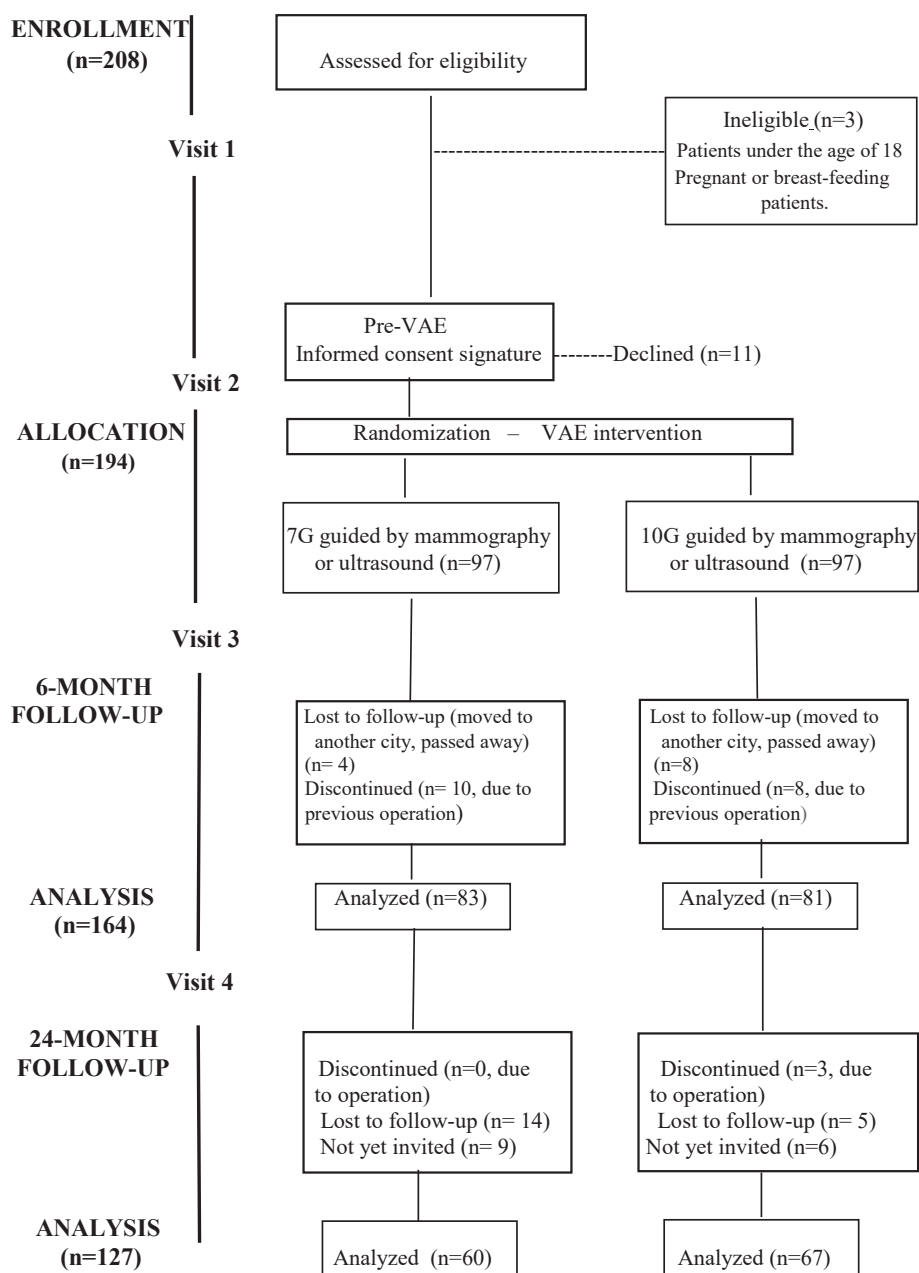


Fig. 1. CONSORT (Consolidated Standards of Reporting Trials) flow diagram.

## 2. Materials and methods

### 2.1. Trial population

This was a single-center, single-blind, randomized trial. Written informed consent was obtained from all the patients. The study was conducted in accordance with the Declaration of Helsinki and the principles of good clinical practice. This clinical trial was reported according to the Consolidated Standards of Reporting Trials (CONSORT) guidelines [32] (Fig. 1).

Patients with ultrasound-visible lesions of <30 mm in size, corresponding to BI-RADS 2 to 4a [8] and a biopsy confirmation corresponding to a B2 or B3 [6,7] lesion, were included in the study. Patients with BI-RADS 3 and BI-RADS 4a microcalcifications measuring <15 mm with or without a previous biopsy were also eligible. Patients aged <18 years, pregnant patients, and breastfeeding patients were excluded. Moreover, patients who were unable to understand or sign the informed consent form were excluded. After obtaining informed consent, each individual was randomized to a procedure using either a 7G (3.8 mm) or 10G (2.7 mm) needle size. No other stratification was performed. We used block randomization in blocks of 40 patients with allocation concealment. Needle-size mandates were enclosed in sequentially numbered opaque envelopes, and selection was performed by an external administrator.

None of the patients included in the study had any underlying diseases that would interfere with the VAE procedure.

### 2.2. Outcomes

Complete excision was one of the primary endpoints. This outcome was primarily defined by visual assessment by a radiologist who performed the VAE and confirmed the absence of residual lesions in the excised area. Subsequently, we crosschecked these results with patients at the 6- and 24- month follow-up.

In this study, we attempted to overcome the issue of radicality by sending separate, numbered sequential tissue sample containers for analysis, where the first container contained the visualized lesion and the remaining two contained increasingly distant non-lesion tissue. This provided a favorable test to understand whether the completeness of the procedure can be accurately evaluated using imaging and histopathology together, which would be a prerequisite for using VAE for malignant lesions in the future [33–35].

We defined a VAE procedure as “macroscopically” excised by the number of the containers that have been obtained during every procedure. We additionally defined a VAE procedure as “microscopically” excised as having only normal tissue in the last container after the histopathological examination.

Procedure time, defined as the time from the start of the administration of local anesthesia until the final removal of the excision needle and placement of the marker, was another primary endpoint.

### 2.3. Excision procedure

For the excision of the lesions, we used the EnCor EnSpire™ Breast Biopsy System already in clinical use, primarily for biopsies, at our department. All masses were visible on ultrasonography and excised using a Philips Epiq Elite ultrasonography machine for guidance. All microcalcifications that were included in the study were excised stereotactically using the Hologic Selenia® Dimensions® tomosynthesis system. The location of the lesion within the breast and the distance to sensitive anatomical structures (nipple, skin, or muscle) were documented in millimeters (mm), as was the size of the target lesion. The morphology of the extraductal masses was documented according to their margins as circular, oval, or irregular (Supplementary Fig. S1).

For both guidance methods, the procedure was performed by one operator with two assistants, with the goal of achieving complete

radiological excision of the lesion, i.e., when the lesion was no longer visible through image guidance. Both the radiologists who performed the procedures exclusively practiced breast radiology. The main operator had a 10-year experience with VAB under stereotactic guidance, had performed >300 VAB procedures and >50 ultrasound-guided VAE procedures at the start of the study, and was defined as experienced. The other operator had no previous experience with ultrasound-guided VAE and was defined as inexperienced; however, she had >5 years of experience with VAB under stereotactic guidance and had performed >100 VAB procedures. The categorization was based on previously published data [36,37] where the success of the procedure and the total operational time was significantly improved after 20–30 procedures. An inexperienced radiologist performed only ultrasound-guided procedures, and the allocation process between the experienced and inexperienced radiologists was completely random. Overall, 10 % of the total cases performed by inexperienced radiologists would potentially provide sufficient results to analyze the difference with experienced radiologists without risking a major BIAS in the rest of our results.

A detailed analysis of the excision procedure is available as [Supplementary Material \(Supplementary Materials and Methods\)](#).

To evaluate the completeness of the excision, the excised tissue was placed in three containers with sequential samples. The first container would contain the excised lesion to the point of complete radiological excision; no remaining lesion would be observed on mammography or ultrasound (visual confirmation by the performer). The subsequent two, meanwhile, would presumably contain normal tissue surrounding the target lesion. The radiologists’ assessment of completeness was categorized as macroscopically complete (two or three containers) or partial (one container). Because the goal was to have at least two containers with material to send to the pathologists for their own analysis we decided to name “one container sampling” as “macroscopically partial.” The main criterion for a radiologist to not perform additional sampling would be the subjective decision from that there would be a high risk for damaging sensitive areas surrounding the area of interest inclusive excessive bleeding. Another reason could be the increased stress experienced by the patient in completing the procedure.

At the end of each procedure, the radiologist documented the visual assessment of the excised area as completely excised.

Before removing the needle, the operator rinsed the area draining blood through the needle to ensure a clear view and a more accurate visual assessment of radicality. At the end of the procedure, a Seno-mark™ Ultra-Breast Tissue Marker was placed in the resection area for follow-up assessment. All samples were sent to the Pathology Department with a request for a separate assessment of each container.

On needle removal, cold compression was applied on the excision area for at least 10 min. After confirming the absence of active bleeding, the incision area was covered with sterile strips and bandages. The patient was discharged with analgesics (500 mg paracetamol), with instructions to continue the same dosage every 6 h for a total of 48 h for stable pain relief. The patients were instructed to avoid substantial physical activity for 48 h. Physical findings and short-term complications were assessed and documented through a telephone call on day 15. Patients with more severe complications were referred to the breast surgery department.

Procedure time, defined as the total time of the VAE procedure from the placement of local anesthesia until the placement of the marker, was documented by a nurse by recording the time on the lab computer. The “total doctor time” was measured from the radiologist’s entrance into the examination room to perform the excision until leaving the room following the completion of the procedure.

Follow-up examinations were performed 6 and 24 months after the procedure using the same modality (mammography or ultrasound) used to guide the VAE procedure. A visual radiological assessment of completeness was repeated and any patient-reported long-term complications were documented.

### 2.4. Statistical analysis

Statistical analysis is presented as [Supplementary Material](#) (Statistical analysis).

## 3. Results

### 3.1. Study population

Patients were enrolled between November 2019 and August 2022. A total of 208 patients were screened and enrolled in this study. Following withdrawal of consent, the trial population comprised 194 patients. Characteristics of the study population are summarized in (Table 1). Only minor differences were observed between the randomization arms.

### 3.2. Description of radiology assessment of lesions

Stereotactically, 36 (19 %) areas of microcalcification were excised from 36 patients: 18 with a 7G needle size and 18 with a 10G needle. All areas of microcalcifications were excised by an experienced radiologist. Under ultrasound-guidance, 158 (81 %) masses were excised from 158 patients: 79 with a 7G needle size and 79 with a 10G one. Of the 158 masses, 69 were described as circular/oval, 45 as irregular, and 44 as intraductal. Seventeen masses were excised by a non-experienced radiologist, and 141 by an experienced radiologist.

### 3.3. Description of sequential sampling performance

Of the 194 excisions, 135 (70 %) were performed with two or three subsequent containers and defined as macroscopically excised, whereas in 59 (30 %), the procedure was stopped after only one container.

**Table 1**  
Study population characteristics.

	Intervention-needle size		
	All (n = 194)	7G (n = 97)	10 G (n = 97)
Mean patient age, years		51.6	48.5
Mean lesion size, mm		10.3 (2–25)	10.7 (4–25)
Lesion type according to primary biopsy, n (%)			
– Normal tissue	11 (5,5%)	5	6
– Fibroadenoma/fibroadenosis	42 (21,5%)	21	21
– Papillary with or without atypia	79 (40,5%)	40	39
– ADH	18 (9,5%)	8	10
– FEA	4 (2 %)	2	2
– ALH/CLCIS	6 (3 %)	5	1
– Radial scar/complex lesion	5 (2,5%)	2	3
– Hemangioma	1 (0,5%)	0	1
– PASH	1 (0,5%)	0	1
– No biopsy	27 (14 %)	14	13
Radiological appearance			
Microcalcifications	36 (18.5 %)	18	18
Masses	158 (81.5 %)	79	79
–circular/oval	69	32	37
–irregular	45	23	22
–intraductal	44	24	20
Radiologist, n (% of masses excised)		(n = 79)	(n = 79)
– More experienced		72 (91 %)	69 (87.5 %)
– Less experienced		7 (9 %)	10 (12.5 %)
Number of containers			
1	59 (30 %)	29	30
2 or 3	135 (70 %)	68	67

ADH, atypical ductal hyperplasia; FEA, fibroepithelial atypia; ALH/CLCIS, atypical lobular hyperplasia/classical lobular cancer in situ; PASH, pseudoangiomatous stromal hyperplasia.

### 3.4. Description of histopathology after VAE

A detailed analysis of the different lesion types and their histopathology is presented in ([Supplementary Table S1](#)). Of the 194 excised lesions, 112 were defined as B3 on primary histopathology, 44 as B2, and 11 as B1 while 27 had no biopsy prior to VAE (microcalcifications). The decision for performing VAE on patients with B1 areas was taken on multidisciplinary conference and was based on palpable findings that were prominent despite absence of radiological findings.

### 3.5. Description of patients undergoing subsequent surgery

18 (9 %) patients underwent subsequent surgery after VAE – 10 non-B3 and 8 B3 lesions. Among the non-B3 lesions, all represented small groups of BI-RADS 3 and 4a calcifications and were operated on without primary biopsy after VAE showed DCIS.

Among the B3 lesions, one was assessed as radial scar with the same histopathology as that observed after the core biopsy, VAE, and subsequent surgery. Two lesions were papillomas without atypia on primary biopsy, one of which was upgraded to papillary cancer on VAE and subsequent surgery, while the other was concordantly assessed as a papillom without atypia after VAE and subsequent surgery. One lesion was assessed as ALH after core biopsy, upgraded to DCIS grade 1 after VAE and further to DCIS grade 3 after subsequent surgery. Five of the lesions were assessed as ADH after core biopsy; two were concordantly assessed as ADH after VAE, and only normal tissue after surgery confirming complete excision; two were upgraded to invasive cancer after VAE, of which was concordantly assessed as invasive cancer after surgery and the other showed only normal tissue after subsequent surgery, confirming complete excision; one ADH was upgraded to DCIS grade 1 after VAE, showing normal tissue after subsequent surgery.

### 3.6. Description of patients not undergoing subsequent surgery

The 176 patients who did not undergo surgery were invited for a 6-month follow-up. Twelve of the invited patients did not participate in the study (e.g., moved to another city or passed away). Of the remaining 164 patients, 127 attended the 24-month follow-up period.

The mean distances of the lesions from the nipple, skin, and muscle were 25 mm, 8 mm, and 9 mm, respectively. Of the 59 lesions that were assessed as partially sampled (with only one round of excision and one container), 53 (90 %) were within 5 mm of the nipple, skin, or muscle. Of the 135 lesions that were assessed as completely sampled (i.e., with two or three containers), 92 (68 %) were located within 5 mm of the nipple, skin, or muscle.

### 3.7. Outcome – procedure time

Overall, the mean procedure time was 8.1 min (95 % CI: 7.55–8.56) and the mean doctor time spent in the procedure room was 20.2 min (95 % CI: 19.24–21.15). The mean procedure time was 7.7 min (95 % CI: 7.03–8.30) in the 7G group and 8.5 min (95 % CI: 7.66–9.24) in the 10G group. The mean doctor times were reported as 19.6 (95 % CI: 18.18–21.05) in the 7G group and 20.8 (95 % CI: 19.49–22.05) in the 10G group (p = 0.126). A box plot graph comparing procedure time and total doctor time to needle size is presented on (Fig. 2).

The following parameters were associated with procedure time in univariate regression analysis: patient age (minus 0.22 min per 5 years older), lesion size (plus 0.23 min per mm larger) and normal tissue vs. other biopsy results (plus 2.7 min) (Table 2.1). The adjusted multivariate model (after exclusion of the microcalcifications) (Table 2.2) indicated that a procedure performed by a more experienced radiologist, compared to that performed by a less experienced, the procedure time was reduced by 1.7 min which was significant (p = 0.03). During our learning curve analysis, the mean procedure time was reduced from 10 min to 9 min when we compared the first 9 cases with the last 8 ones (p

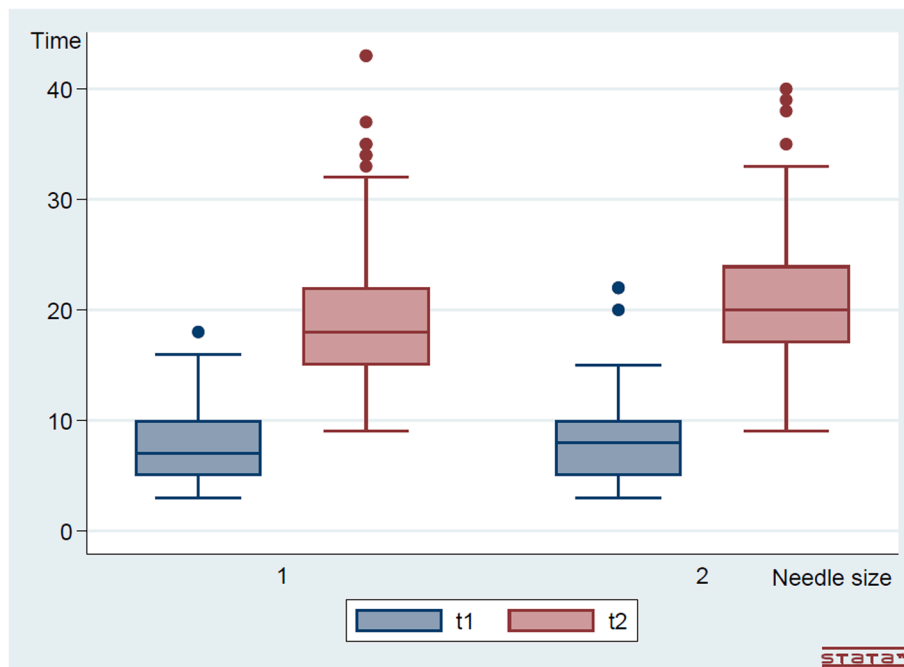


Fig. 2. Box plot graph comparing procedure time (t1) and total doctor time (t2) to needle size (1 = 7G, 2 = 10G).

Table 2.1

Parameters associated with procedure time (minutes) – Univariate analysis.

	Univariate Linear Regression (n = 194)			
	n	Beta	(95 % CI)	p
Needle size: 10G vs 7G	194	0.78	(-0.22 to 1.78)	0.126
Age, per 5 years	194	-0.19	(-0.36 to -0.02)	<b>0.027</b>
Lesion size, per mm	194	0.23	(0.15 to 0.32)	<b>&lt;0.001</b>
Initial biopsy: Normal tissue vs other	164	-1.72	(-3.65 to 0.19)	<b>0.08</b>
Mass vs microcalcifications	194	0.69	(-0.62 to 2.00)	0.300
Radiologist: More vs less experienced	159	-1.72	(-3.52 to 0.86)	0.062

CI, Confidence Interval; Bold text indicate the significant parameters.

Table 2.2

Parameters associated with procedure time (min) – Multivariate analysis (excluding the microcalcifications).

	Multivariate Linear Regression (n = 158)		
	Beta	95 % CI	p
Needle size: 10G vs 7G	0.08	(-0.93 to 1.07)	0.878
Age, per 5 years	-0.10	(-0.27 to 0.63)	0.226
Lesion size	0.27	(0.18 to 0.36)	<b>&lt;0.001</b>
Initial biopsy: Normal tissue vs Other	-1.31	(-3.08 to 0.45)	0.143
Mass vs Microcalcifications	NOT INCLUDED		
Radiologist: More vs Less experienced	-1.78	(-3.39 to -0.17)	<b>0.030</b>

CI, Confidence Interval; Bold text indicate the significant parameters.

= 0.6).

### 3.8. Outcome – Excision completeness

Ninety percent (174/194) of the lesions were completely excised according to the visual assessment of the excised area by the radiologist at the end of the procedure. There was no difference between the 10G needle size, 92 % (89/97), and 7G needle size, 88 % (85/97).

### 3.9. Outcome – Six-month follow-up

Of the 164 patients who attended the 6-month follow-up, 86 % (141/164) showed no residual lesions. There was no statistical difference between the 10G needle size, 81.5 % (66/81) and 7G needle size, 90 % (75/83).

Lesion size was the only parameter associated with 6-month completeness outcome in univariate regression analysis (Table 3.1). At multivariate analysis lesion size remained associated with completeness, whilst having microcalcifications rather than a mass, also showed to have a significant effect on completeness (Table 3.2).

### 3.10. Outcome – 24-month follow-up

Until the data unlock time point of September 15, 2024, 127 of the 164 patients (77 %) had attended their 24-month follow-up. Eighty-two percent (104/127) of those patients had no residual findings at the 6-month follow-up; however, two among the 104 patients showed recurrence at their 24-month follow-up. The recurrence of the first patient was papilloma without atypia in concordance with the initial diagnosis, and the other patient had ADH after VAE and upgraded to DCIS grade 2 post-surgery.

Among the 23 patients with suspicious residual findings during the 6-month follow-up, one had a fibroadenoma that showed progression in size, and supplementary surgery confirmed a benign diagnosis; nine of those 23 patients, showed complete regression of the findings at the 24-

Table 3.1

Univariate analysis of parameters affecting completeness of excision at 6-month follow-up.

	Univariate Logistic Regression (n = 164)		
	Beta	p	(95 % CI)
Number of containers	0.004	0.988	(-0.55 to 0.56)
Lesion size, per mm	0.206	<b>0.001</b>	(0.12 to 0.28)
Needle size: 10G vs 7G	0.642	0.137	(-0.20 to 1.48)
Mass vs microcalcifications	0.758	0.153	(-0.28 to 1.79)
Radiologist: More vs Less experienced	-1.673	0.001	(-2.14 to -1.20)

CI, Confidence Interval; Bold text indicate the significant parameters.



**Table 3.2**

Multivariate analysis of parameters affecting completeness of excision at 6-month follow-up.

Multivariate Logistic Regression (n = 164)			
	Beta	p	(95 % CI)
Number of containers	-0.527	0.151	(-1.24 to 0.19)
<b>Lesion size, per mm</b>	0.301	<b>0.001</b>	(0.18 to 0.42)
Needle size: 10G vs 7G	0.915	0.109	(-0.20 to 2.03)
<b>Mass vs microcalcifications</b>	3.277	<b>0.001</b>	(1.63 to 4.92)

CI, Confidence Interval; Bold text indicate the significant parameters.

month follow-up, which was interpreted as scar tissue; 10 were having fibroadenomas with a primary size between 15–25 mm; one had a hemangioma with a size of 25 mm and two had benign microcalcifications.

At the end of the 24-month follow-up, 88 % (112/127) of the lesions had been completely excised. Of the 127 patients, 60 were treated with a 7G needle size and 67 using with a 10G needle size. Ninety-three percent (56/60) of excision completeness was achieved with the 7G needle size and 84 % (56/67) was achieved with the 10G needle size, without any statistical difference.

#### 4. Discussion

In this randomized clinical trial, which focused primarily on breast lesions with uncertain malignant potential, we found that there was no overall difference between using 7G needles and 10G needles in terms of procedure time and excision completeness. Based on regression analysis, we found that lesion size was the only consistent and statistically significant determinant of both outcomes.

We observed a slight difference in point estimates, for procedure time 7.8 min for 10G needle and 8.5 min for 7G needle, and for excision completeness 90 % for 7G needle and 82 % for 10G needle. It cannot be ruled out that a similar magnitude of differences would have been found statistically significant in a trial with a larger study population and hence more statistical power. Kim et al. [40] used an 8 G needle for lesions 15–30 mm in diameter and an 11 G needle for lesions smaller than 15 mm. Parker stated that using an 8G needle for excising lesions > 15 mm instead of the smaller 11G needle was preferable, arguing that a greater amount of tissue was obtained with larger needles [41].

VAE for BI-RADS 3 and 4a microcalcifications under the guidance of stereotactic mammography resulted in subsequent surgery in 28 % of the cases compared with 7 % of the other lesions, a difference that could be caused by difficulties delineating the complete extent of microcalcifications. Only 9/36 (25 %) cases with microcalcifications were deemed both macroscopically and microscopically completely excised following the procedure and at the 6-month follow-up. This underlines the results of previous studies [48–50] suggesting VAB should be performed primarily followed by surgery rather than VAE.

In our study, the total doctor time in the examination room (20.2 min) was slightly shorter than that reported by Lee et al. [31]. The procedure time in our study (8.1 min) was in line with the results from Wang et al., who reported times with a 7G needle of 6.6 min (2–12 min) [18]. Times were markedly shorter than with the Mammotome™ 11G, as reported by Baez et al. [16], reporting a procedure time of 20–35 min using ultrasound guidance but without stating the initial point for procedure time. We must acknowledge the technological limitations of this instrument at the time (2003), particularly the significant restrictions in manipulation and handling due to its attachment to an arm. Besides focusing on B3 lesions, in our study, we decided to include patients with normal tissue after the initial biopsy (n = 11). This was owing to the presence of a palpable lesion and an ultrasound finding that prompted further action. These patients had a longer procedure time, probably owing to the uncertainty of the findings, which required a more thorough examination of the area.

We used an innovative method in this study to evaluate the completeness of excised lesions by sequential sampling in three containers. The first included all samples from the visual lesion, and the others contained increasingly distant visually normal breast tissue. Obtaining tissue for multiple containers was not possible for all patients, primarily because of the proximity of the lesion to sensitive structures such as the nipple and skin. An important finding, however, was that 92 % of the lesions that were deemed both macroscopically (by the radiologist) and microscopically (by the pathologist) completely excised showed no residual findings at the 6-month follow-up, which increased to 97.5 % at the 24-month follow-up without additional intervention confirming scar tissue misinterpreted as residual disease at the 6-month follow-up. These results are promising for the use of this technique for accurate assessment of excision completeness.

In line with previous studies [10,40,42], we confirmed the inability of direct post-procedure image analysis to accurately confirm the completeness of excision and showed that long-term follow-up imaging is advisable, preferably a minimum of 24-months. The percentage of completeness at the 6-month follow-up, in our study was 86 %, which is in concordance with the results of previous studies [10,24,43–46]. Yom et al. [47] argued that in the early stages after VAE, it is challenging to differentiate the actual residual lesion from a hematoma or post-VAE scar. Therefore, to judge the results of the excision, repetitive follow-up examinations are needed over a long interval of time (Supplementary Fig. S4). At the 33-month follow-up, they found fewer residual lesions (6.5 %) than at the 24-month follow-up (10 %), whereas residual masses developed in 1.1 % of the cases with no sign of residual lesions at 24 months. These results are consistent with the 24-month follow-up findings from our study.

Our data revealed a nonsignificant learning curve for inexperienced radiologists, which can correlate with that from other studies showing impressive proficiency in performing VAB by radiologists with previous experience in ultrasound-guided procedures [36,38,39].

One of the limitations of our study design was that it was performed at a single center which may pose a challenge for the external validity of the outcome. Another limitation is that 24 % of the included patients did not attend the 24 month follow-up examination, which reduced the statistical power and possibly introduced selection bias.

In conclusion, we found no significant difference in procedure time or in excision completeness related to using a 7G or 10G needle. There was, however, an association between lesion size and both outcomes.

#### CRedit authorship contribution statement

**Athanasios Zouzou:** Writing – review & editing, Writing – original draft, Visualization, Software, Resources, Project administration, Methodology, Investigation, Funding acquisition, Formal analysis, Data curation, Conceptualization. **Irma Fredriksson:** Writing – review & editing, Validation, Supervision, Resources, Project administration, Methodology, Formal analysis. **Andreas Karakatsanis:** Writing – review & editing, Validation, Supervision, Resources, Methodology, Conceptualization. **Iliana Aristokleous:** Validation, Resources. **Theodoros Foukakis:** Writing – review & editing, Validation, Supervision, Resources, Methodology, Formal analysis. **Fredrik Strand:** Writing – review & editing, Writing – original draft, Visualization, Validation, Supervision, Software, Resources, Project administration, Methodology, Investigation, Funding acquisition, Formal analysis, Data curation, Conceptualization.

#### Declaration of competing interest

The authors declare the following financial interests/personal relationships which may be considered as potential competing interests: [Athanasios Zouzou reports financial support was provided by Becton Dickinson and Company. Athanasios Zouzou reports financial support was provided by Region Stockholm. If there are other authors, they

declare that they have no known competing financial interests or personal relationships that could have appeared to influence the work reported in this paper].

## Acknowledgments

This study was supported by grants from Region Stockholm, Karolinska Institutet, Sweden and BD®. The funding sources had no role in the data analysis, interpretation, writing of the article, or decision to submit the article. The authors would like to thank assistant professor Fuat Celebioglu, breast surgeon at South General Hospital for referring numerous patients to our department for inclusion in the study.

## Appendix A. Supplementary material

Supplementary data to this article can be found online at <https://doi.org/10.1016/j.ejrad.2024.111895>.

## References

- S.E. Pinder, A. Shaaban, R. Deb, et al., NHS Breast Screening multidisciplinary working group guidelines for the diagnosis and management of breast lesions of uncertain malignant potential on core biopsy (B3 lesions), *Clin. Radiol.* 73 (8) (2018) 682–692, <https://doi.org/10.1016/j.crad.2018.04.004>.
- C.J. Rageth, E.A. O'Flynn, C. Comstock, et al., First International Consensus Conference on lesions of uncertain malignant potential in the breast (B3 lesions), *Breast Cancer Res. Treat.* 159 (2) (2016) 203–213, <https://doi.org/10.1007/s10549-016-3935-4>.
- C.J. Rageth, E.A.M. O'Flynn, K. Pinker, et al., Second International Consensus Conference on lesions of uncertain malignant potential in the breast (B3 lesions), *Breast Cancer Res. Treat.* 174 (2) (2019) 279–296, <https://doi.org/10.1007/s10549-018-05071-1>.
- C. Elfgen, C. Leo, R.A. Kubik-Huch, et al., Third International Consensus Conference on lesions of uncertain malignant potential in the breast (B3 lesions), *Virchows Arch.* 483 (1) (2023) 5–20, <https://doi.org/10.1007/s00428-023-03566-x>.
- I.T. Rubio, L. Wyld, L. Marotti, et al., European guidelines for the diagnosis, treatment and follow-up of breast lesions with uncertain malignant potential (B3 lesions) developed jointly by EUSOMA, EUSOBI, ESP (BWG) and ESSO, *Eur. J. Surg. Oncol.* 50 (1) (2024) 107292, <https://doi.org/10.1016/j.ejso.2023.107292>.
- N. Perry, M. Broeders, C. de Wolf, S. Törnberg, R. Holland, L. von Karsa, European guidelines for quality assurance in breast cancer screening and diagnosis. Fourth edition—summary document, *Ann. Oncol.* 19 (4) (2008) 614–622, <https://doi.org/10.1093/annonc/mdm481>.
- A.H.S. Lee, S.E. Pinder, An overview of B coding of breast core biopsy categorisation and management implications, *Diagn. Histopathol.* 30 (2) (2024) 132–140, <https://doi.org/10.1016/j.mpdhp.2023.11.004>.
- Magny SJ, Shikhman R, Keppeke AL. Breast Imaging Reporting and Data System. *StatPearls*. StatPearls Publishing Copyright © 2022, StatPearls Publishing LLC.; 2022.
- L. Liberman, J.B. Kaplan, E.A. Morris, A.F. Abramson, J.H. Menell, D.D. Dershaw, To excise or to sample the mammographic target: what is the goal of stereotactic 11-gauge vacuum-assisted breast biopsy? *AJR Am. J. Roentgenol.* 179 (3) (2002) 679–683, <https://doi.org/10.2214/ajr.179.3.1790679>.
- R.E. Fine, P.Z. Israel, L.C. Walker, et al., A prospective study of the removal rate of imaged breast lesions by an 11-gauge vacuum-assisted biopsy probe system, *Am. J. Surg.* 182 (4) (2001) 335–340, [https://doi.org/10.1016/s0002-9610\(01\)00723-1](https://doi.org/10.1016/s0002-9610(01)00723-1).
- A.D. Mosier, J. Keylock, D.V. Smith, Benign papillomas diagnosed on large-gauge vacuum-assisted core needle biopsy which span <1.5 cm do not need surgical excision, *Breast J.* 19 (6) (2013) 611–617, <https://doi.org/10.1111/tbj.12180>.
- S. Monib, S. Mukerji, S. Narula, Vacuum-assisted breast biopsy system: no innovation without evaluation, *Cureus* 13 (1) (2021) e12649, <https://doi.org/10.7759/cureus.12649>.
- N. Tagaya, A. Nakagawa, Y. Ishikawa, T. Oyama, K. Kubota, Experience with ultrasonographically guided vacuum-assisted resection of benign breast tumors, *Clin. Radiol.* 63 (4) (2008) 396–400, <https://doi.org/10.1016/j.crad.2007.06.012>.
- R.E. Fine, B.A. Boyd, P.W. Whitworth, J.A. Kim, J.K. Harness, W.E. Burak, Percutaneous removal of benign breast masses using a vacuum-assisted hand-held device with ultrasound guidance, *Am. J. Surg.* 184 (4) (2002) 332–336, [https://doi.org/10.1016/s0002-9610\(02\)00951-0](https://doi.org/10.1016/s0002-9610(02)00951-0).
- R.E. Fine, P.W. Whitworth, J.A. Kim, J.K. Harness, B.A. Boyd, W.E. Burak Jr., Low-risk palpable breast masses removed using a vacuum-assisted hand-held device, *Am. J. Surg.* 186 (4) (2003) 362–367, [https://doi.org/10.1016/s0002-9610\(03\)00263-0](https://doi.org/10.1016/s0002-9610(03)00263-0).
- E. Baez, A. Huber, M. Vetter, B.J. Hackelöer, Minimal invasive complete excision of benign breast tumors using a three-dimensional ultrasound-guided mammotome vacuum device, *Ultrasound Obstet Gynecol.* 21 (3) (2003) 267–272, <https://doi.org/10.1002/uog.74>.
- U. Krainick-Strobel, B. Huber, I. Majer, et al., Complete extirpation of benign breast lesions with an ultrasound-guided vacuum biopsy system, *Ultrasound Obstet Gynecol.* 29 (3) (2007) 342–346, <https://doi.org/10.1002/uog.3840>.
- Z.L. Wang, G. Liu, Y. Huang, W.B. Wan, J.L. Li, Percutaneous excisional biopsy of clinically benign breast lesions with vacuum-assisted system: comparison of three devices, *Eur. J. Radiol.* 81 (4) (2012) 725–730, <https://doi.org/10.1016/j.ejrad.2011.01.059>.
- S.P. Povoski, R.E. Jimenez, A comprehensive evaluation of the 8-gauge vacuum-assisted Mammotome(R) system for ultrasound-guided diagnostic biopsy and selective excision of breast lesions, *World J. Surg. Oncol.* 5 (2007) 83, <https://doi.org/10.1186/1477-7819-5-83>.
- S. Liu, J.L. Zou, F.L. Zhou, Y.M. Fang, Efficacy of ultrasound-guided vacuum-assisted Mammotome excision for management of benign breast diseases: analysis of 1267 cases, *Nan Fang Yi Ke Da Xue Xue Bao.* 37 (8) (2017) 1121–1125, <https://doi.org/10.3969/j.issn.1673-4254.2017.08.20>.
- G. Panzironi, G. Moffa, F. Galati, F. Pediconi, Ultrasound-guided 8-Gauge vacuum-assisted excision for selected B3 breast lesions: a preliminary experience, *Radiol. Med.* 127 (1) (2022) 57–64, <https://doi.org/10.1007/s11547-021-01429-6>.
- S.H. Heywang-Köbrunner, A. Heinig, U. Schaumlöffel, et al., MR-guided percutaneous excisional and incisional biopsy of breast lesions, *Eur. Radiol.* 9 (8) (1999) 1656–1665, <https://doi.org/10.1007/s003300050905>.
- S. Schradang, K. Strobel, A. Keulers, T. Dirrichs, C.K. Kuhl, Safety and efficacy of magnetic resonance-guided vacuum-assisted large-Volume Breast Biopsy (MR-Guided VALB), *Invest Radiol.* 52 (3) (2017) 186–193, <https://doi.org/10.1097/rli.0000000000000331>.
- J.P. Salazar, I. Miranda, J. de Torres, et al., Percutaneous ultrasound-guided vacuum-assisted excision of benign breast lesions: a learning curve to assess outcomes, *Br. J. Radiol.* 92 (1094) (2019) 20180626, <https://doi.org/10.1259/bjr.20180626>.
- S.C. Chen, H.R. Yang, T.L. Hwang, M.F. Chen, Y.C. Cheung, S. Hsueh, Intraoperative ultrasonographically guided excisional biopsy or vacuum-assisted core needle biopsy for nonpalpable breast lesions, *Ann. Surg.* 238 (5) (2003) 738–742, <https://doi.org/10.1097/01.sla.0000094439.93918.31>.
- E.Y. Ko, Y.A. Bae, M.J. Kim, K.S. Lee, Y. Lee, L.S. Kim, Factors affecting the efficacy of ultrasound-guided vacuum-assisted percutaneous excision for removal of benign breast lesions, *J. Ultrasound Med.* 27 (1) (2008) 65–73, <https://doi.org/10.7863/jum.2008.27.1.65>.
- T. Perretta, F. Lamacchia, D. Ferrari, et al., Evaluation of ultrasound-guided 8-gauge vacuum-assisted excision system for the removal of US-detectable breast lesions, *Anticancer Res.* 40 (3) (2020) 1719–1729, <https://doi.org/10.21873/anticancer.14125>.
- E.M.F. van de Voort, T. Klem, G.M. Struik, E. Birnie, R. Sinke, A. Ghandi, Patient reported cosmetic outcome after vacuum assisted excision of benign breast lesions: a cross-sectional study, *Br. J. Radiol.* 93 (1114) (2020) 20190994, <https://doi.org/10.1259/bjr.20190994>.
- H.L. Park, J. Hong, Vacuum-assisted breast biopsy for breast cancer, *Gland Surg.* 3 (2) (2014) 120–127, <https://doi.org/10.3978/j.issn.2227-684X.2014.02.03>.
- S. Venkataraman, V. Dialani, H.L. Gilmore, T.S. Mehta, Stereotactic core biopsy: Comparison of 11 gauge with 8 gauge vacuum assisted breast biopsy, *Eur. J. Radiol.* 81 (10) (2012) 2613–2619, <https://doi.org/10.1016/j.ejrad.2011.10.027>.
- K.E. Lee, H.H. Kim, H.J. Shin, J.H. Cha, Stereotactic biopsy of the breast using a decubitus table: comparison of histologic underestimation rates between 11- and 8-gauge vacuum-assisted breast biopsy, *Springerplus.* 2 (2013) 551, <https://doi.org/10.1186/2193-1801-2-551>.
- K.F. Schulz, D.G. Altman, D. Moher, CONSORT 2010 statement: Updated guidelines for reporting parallel group randomised trials, *Int. J. Surg. (London, England).* 9 (8) (2011) 672–677, <https://doi.org/10.1016/j.ijsu.2011.09.004>.
- P. Cusumano, W.P. Polkowski, H. Liu, R. Schulz-Wendtland, J. Janssens, Percutaneous tissue acquisition: a treatment for breast cancer? Vacuum-assisted biopsy devices are not indicated for extended tissue removal, *Eur. J. Cancer Prev.* 17 (4) (2008) 323–330, <https://doi.org/10.1097/CEJ.0b013e3283048e0f>.
- G. Gajdos, M. Levy, Z. Herman, G. Herman, I.J. Bleiweis, P.I. Tartter, Complete removal of nonpalpable breast malignancies with a stereotactic percutaneous vacuum-assisted biopsy instrument, *J. Am. Coll. Surg.* 189 (3) (1999) 237–240, [https://doi.org/10.1016/s1072-7515\(99\)00133-7](https://doi.org/10.1016/s1072-7515(99)00133-7).
- J.H. Park, S.E. Ahn, S. Kim, M.J. Kwon, Y.J. Suh, D. Kim, Complete surgical excision is necessary following vacuum-assisted biopsy for breast cancer, *Curr. Oncol.* 29 (12) (2022) 9357–9364, <https://doi.org/10.3390/curroncol29120734>.
- L. Liberman, C.L. Benton, D.D. Dershaw, A.F. Abramson, L.R. LaTrenta, E. A. Morris, Learning curve for stereotactic breast biopsy: how many cases are enough? *AJR Am. J. Roentgenol.* 176 (3) (2001) 721–727, <https://doi.org/10.2214/ajr.176.3.1760721>.
- H.S. Park, C.W. Jeon, Learning curve for breast mass excision using a vacuum-assisted biopsy system, *Minim Invasive Ther Allied Technol.* 23 (4) (Aug 2014) 235–240, <https://doi.org/10.3109/13645706.2014.894918>.
- G.C. Zografos, F. Zagouri, T.N. Sergentanis, Vacuum-assisted breast biopsy: an easy-to-learn procedure? *Am. J. Surg.* 196 (5) (2008) 798, <https://doi.org/10.1016/j.amjsurg.2007.10.008>.
- D.R. Holmes, M.J. Silverstein, A minimally invasive breast biopsy clinic: an innovative way to teach breast fellows how to perform breast ultrasound and ultrasound-guided breast procedures, *Am. J. Surg.* 192 (4) (2006) 439–443, <https://doi.org/10.1016/j.amjsurg.2006.06.007>.
- M.J. Kim, E.K. Kim, J.Y. Kwak, et al., Nonmalignant papillary lesions of the breast at US-guided directional vacuum-assisted removal: a preliminary report, *Eur. Radiol.* 18 (9) (2008) 1774–1783, <https://doi.org/10.1007/s00330-008-0960-7>.
- Stavros AT. *Breast Ultrasound*. Stavros AT. Lippincott Williams & Wilkins; 2003.

- [42] J.R. Simon, C.L. Kalbhen, R.A. Cooper, M.E. Flisak, Accuracy and complication rates of US-guided vacuum-assisted core breast biopsy: initial results, *Radiology* 215 (3) (2000) 694–697, <https://doi.org/10.1148/radiology.215.3.r00jn37694>.
- [43] S.H. Lee, E.K. Kim, M.J. Kim, H.J. Moon, J.H. Yoon, Vacuum-assisted breast biopsy under ultrasonographic guidance: analysis of a 10-year experience, *Ultrasonography* 33 (4) (2014) 259–266, <https://doi.org/10.14366/usg.14020>.
- [44] O. Buğdaycı, H. Kaya, E. Arıbal, Ultrasound guided therapeutic excisional vacuum assisted biopsy in breast fibroadenomas, *J. Breast Health*. 13 (2) (2017) 74–76, <https://doi.org/10.5152/tjbh.2017.3038>.
- [45] M. Hahn, U. Krainick-Strobel, T. Toellner, et al., Interdisciplinary consensus recommendations for the use of vacuum-assisted breast biopsy under sonographic guidance: first update 2012, *Ultraschall Med.* 33 (4) (2012) 366–371, <https://doi.org/10.1055/s-0032-1312831>.
- [46] I.C. Bennett, The changing role of vacuum-assisted biopsy of the breast: a new prototype of minimally invasive breast surgery, *Clin. Breast Cancer*. 17 (5) (2017) 323–325, <https://doi.org/10.1016/j.clbc.2017.03.001>.
- [47] C.K. Yom, B.I. Moon, K.J. Choe, H.Y. Choi, Y.L. Park, Long-term results after excision of breast mass using a vacuum-assisted biopsy device, *ANZ J. Surg.* 79 (11) (2009) 794–798, <https://doi.org/10.1111/j.1445-2197.2009.05103.x>.
- [48] S. Penco, S. Rizzo, A.C. Bozzini, et al., Stereotactic vacuum-assisted breast biopsy is not a therapeutic procedure even when all mammographically found calcifications are removed: analysis of 4,086 procedures, *AJR Am. J. Roentgenol.* 195 (5) (2010) 1255–1260, <https://doi.org/10.2214/ajr.10.4208>.
- [49] S. Bianchi, S. Caini, G. Renne, et al., Positive predictive value for malignancy on surgical excision of breast lesions of uncertain malignant potential (B3) diagnosed by stereotactic vacuum-assisted needle core biopsy (VANCB): a large multi-institutional study in Italy, *Breast*. 20 (3) (2011) 264–270, <https://doi.org/10.1016/j.breast.2010.12.003>.
- [50] G. Esen, B. Tutar, C. Uras, Z. Calay, Ü. İnce, O. Tutar, Vacuum-assisted stereotactic breast biopsy in the diagnosis and management of suspicious microcalcifications, *Diagn. Interv. Radiol.* 22 (4) (2016) 326–333, <https://doi.org/10.5152/dir.2015.14522>.