

Acute Vestibular Syndrome Unmasking an *RFC1*-Spectrum Disorder

Luca Verrecchia,¹ Victor Alm,² Håkan Thonberg,³ Felix Lenner,⁴ Aida Paivandy,⁴ Lars Feuk,^{4,5} Anna Lindstrand,^{3,6} Daniel Nilsson,^{3,6} and Martin Paucar^{2,7}

Neurol Genet 2025;11:e200238. doi:10.1212/NXG.000000000200238

Correspondence
Dr. Paucar
martin.paucar-arce@
regionstockholm.se

Abstract

Objectives

Since the discovery of biallelic pentanucleotide expansions in *RFC1* as the cause of cerebellar ataxia, neuropathy, vestibular areflexia syndrome, a wide and growing clinical spectrum has emerged. In this article, we report a man with acute vestibular syndrome that likely unmasked a *RFC1*-spectrum disorder.

Methods

Detailed clinical evaluation, neuroimaging, nerve conduction studies, evaluation of vestibular function, and short-read whole-genome sequencing and targeted long-read adaptive sequencing were performed.

Results

Clinical follow-up after acute vestibular syndrome revealed bilateral vestibular areflexia and a gait abnormality with the Scale for the Assessment and Rating of Ataxia score of 5. Brain MRI was normal while 2 electroneurography tests did not show neuropathy. However, severe cough spells raised the suspicion of a *RFC1*-spectrum disorder. WGS screening detected a recessive intronic pentanucleotide expansion in *RFC1*, which was verified and sized using long-read adaptive sequencing.

Discussion

This is an unusual presentation; oscillopsia after an acute vestibular syndrome and cough spells should alert clinicians about a *RFC1*-spectrum disorder, even in the absence of neuropathy and neuroradiologic abnormalities.

Introduction

Adult-onset cerebellar ataxia, neuropathy, vestibular areflexia syndrome (CANVAS) features a slowly progressive presentation with variable expressivity.^{1,2} CANVAS is associated with biallelic pentanucleotide expansions in *RFC1*.²⁻⁴ The clinical presentation is variable with up to 63% of patients displaying all the abnormalities stated in the acronym.²⁻⁶ In this article, we report a man with acute vestibular syndrome unmasking a *RFC1*-spectrum disorder.

Case Description

A 60-year-old White man with a medical history of hypertension treated with amlodipine, irritable bowel disease, and gastroesophageal reflux disease (GERD) with esophagitis was evaluated at the emergency department (ED) because of acute-onset dizziness, nausea, and

¹ENT Unit, Department of Clinical Science, Intervention and Technology, Karolinska Institutet, Stockholm, Sweden; ²Department of Neurology, Karolinska University Hospital, Stockholm, Sweden; ³Department of Clinical Genetics and Genomics, Karolinska University Hospital, Stockholm, Sweden; ⁴Department of Immunology, Genetics and Pathology, Uppsala University, Sweden; ⁵Science for Life Laboratory, Uppsala University, Sweden; ⁶Department of Molecular Medicine and Surgery, Karolinska Institutet, Stockholm, Sweden; and ⁷Department of Clinical Neuroscience, Karolinska Institutet, Stockholm, Sweden.

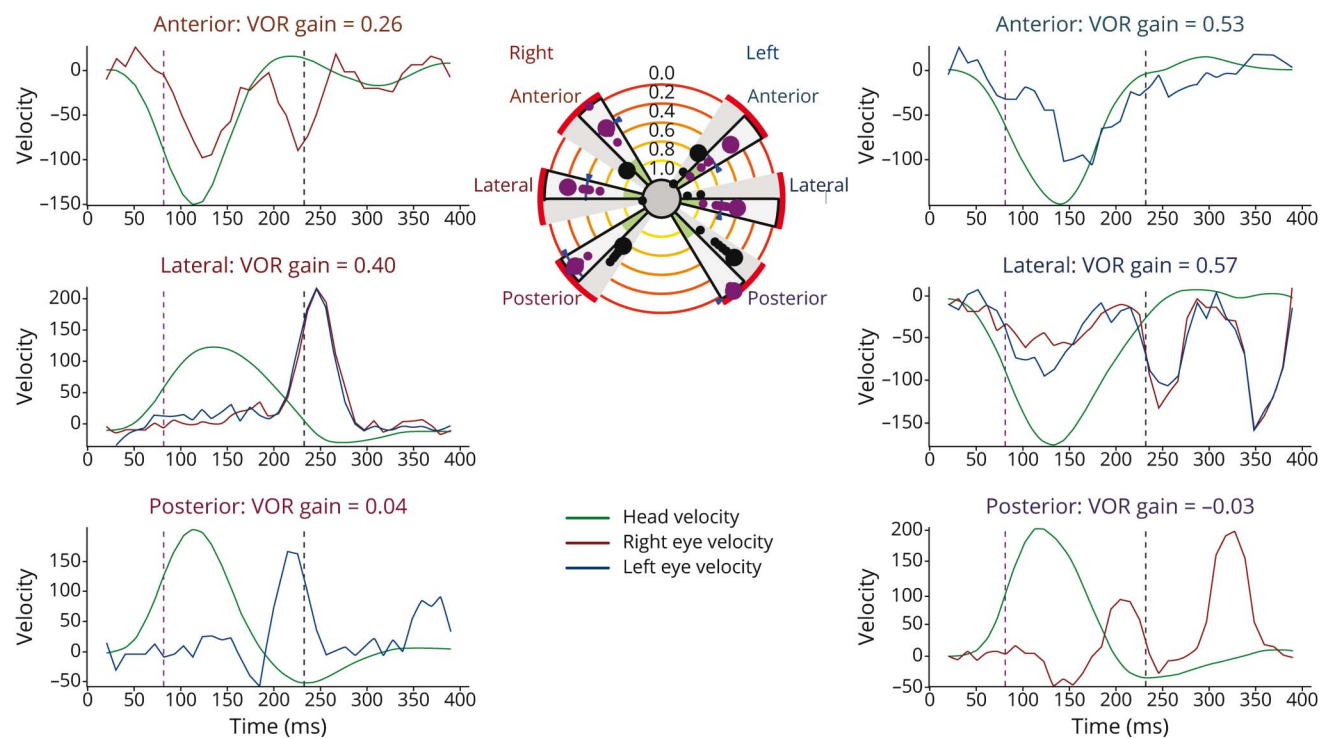
The Article Processing Charge was funded by the authors.

This is an open access article distributed under the terms of the Creative Commons Attribution-Non Commercial-No Derivatives License 4.0 (CCBY-NC-ND), where it is permissible to download and share the work provided it is properly cited. The work cannot be changed in any way or used commercially without permission from the journal.

vomiting at age 59. Before dizziness, the patient was able to jog and bike without difficulties. Physical examination then revealed right-side nystagmus, a positive head impulse test on the left, and absence of skew deviation were present. A reasonable diagnosis of vestibular neuronitis was made, and the patient was treated with prednisolone for 5 days. The patient recovered, but unsteadiness, dynamic oscillopsia, and dizziness persisted for many weeks, motivating a re-assessment. A neuro-otological examination revealed a bilateral vestibular loss on the video head impulse test and vestibular areflexia on the caloric irrigation test (Figures 1 and 2), with no apparent eye movement disorder and a normal audiometry test. Since age 30, the patient had reported severe and recurrent cough spells, often triggered by exertion. These symptoms motivated a referral for neurologic evaluation. There was no family history of neurologic disease. Although the patient's alcohol use was hazardous, he did not meet the criteria for dependency and was able to quit his intake, but his symptoms remained unchanged. An examination using the Scale for the Assessment and Rating of Ataxia yielded 5 points; the patient deviated a few times during tandem gait and had mild dysmetria. Nystagmus and other eye movement abnormalities were again absent and both his speech and muscle tone were normal, but tendon reflexes were absent. Other movement disorders besides ataxia were absent. Previously, his cough

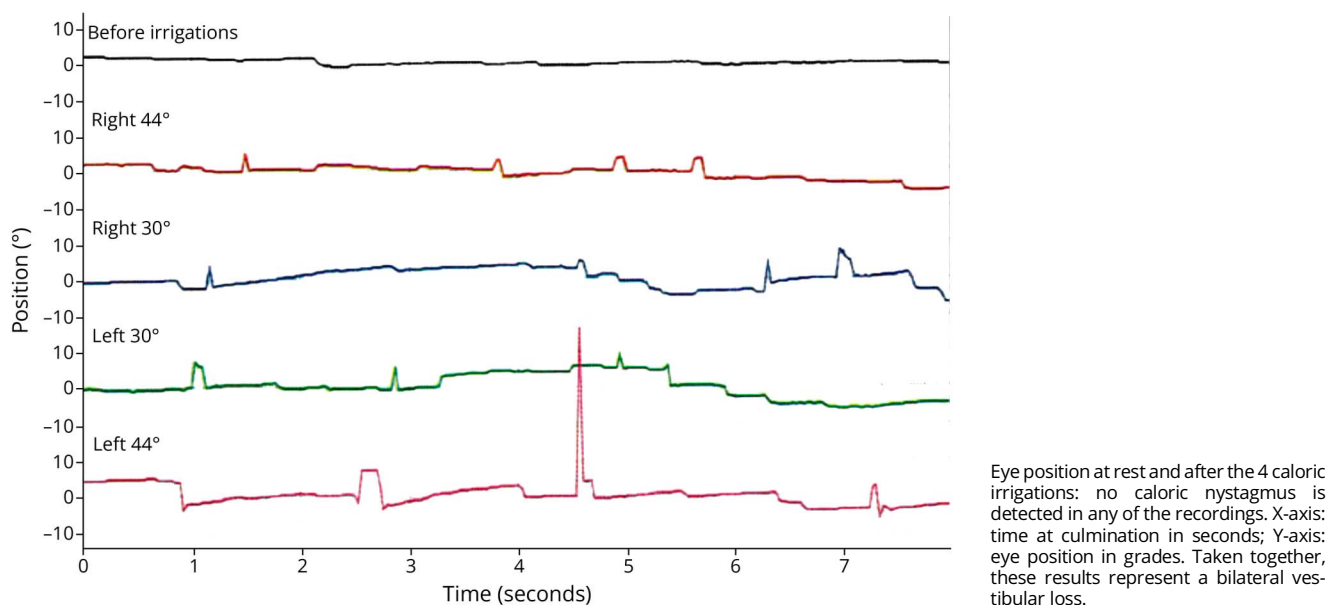
spells had motivated a workup with spirometry, which revealed a moderately obstructive pattern. At the time of diagnosis, the forced expiratory volume in 1 second was initially 3.73 L (85% of predicted) and increased by 8% after bronchodilator administration. Forced expiratory flow at 50% and 25% increased by 12% and 20%, respectively. Previous skin prick tests were positive for birch, timothy grass, and cat. The patient was diagnosed with moderate bronchial asthma and allergic rhinitis. However, treatment with asthma inhalators, montelukast and omeprazole (for GERD), provided minimal relief. Both gabapentin and capsaicin were tried for the cough spells without benefit. The patient denied urinary urgency and constipation, and there were no signs of orthostatism. Brain MRI at age 59 was normal. The patient reported recurrent numbness in his fingers and feet, but 2 electroneurography tests over 1 year were unchanged. In brief, the motor neurography was normal, but the sensory neurography yielded a sensory nerve action potential (SNAP) of 3 μV for the left sural nerve and 15 μV for the left radial nerve, whereas SNAPs from other nerves (median and ulnar) were normal (eTable 1). A quantitative sensory testing found raised thresholds for heat and cold in the feet but not in the hands. Routine laboratory tests and screening for neurometabolic disorders were normal. Neuronal and transglutaminase antibodies were absent. Short-read whole-genome sequencing detected an

Figure 1 Video Head Impulse Test (vHIT) in a Man With a *RFC1*-Spectrum Disorder; Eye/Head Angular Velocity Graphs on the Sides, Showing a Representative vHIT Trial for Each of the 3-Canal Testing per Side



X-axis: milliseconds. VOR gains: mean value for each canal. In the middle, the "canalogram" indicates the spreading of gain responses (violet dots) and larger dots refer to the singular recordings on graphs. Dark dots: gaze refixations. VOR gains <0.8 for lateral canals and <0.6 for anterior/posterior canals are indicative of vestibular loss. VOR = vestibulo-ocular reflex.

Figure 2 Caloric Irrigation Test in a Man With a *RFC1*-Spectrum Disorder



intronic pentanucleotide expansion in *RFC1*, which was confirmed by RP-PCR (eMethods and eFigures 1 and 2). The pentanucleotide expansion size was determined by means of nanopore sequencing; the expanded alleles were 4,300 bp and 4,619 bp (range 4,594–4,642 bp) with sequences (AAAGG)₄(AAGGG)₈₅₅ and (AAAGG)₄(AAGGG)_{–919} (eMethods and eFigure 2). Other nucleotide expansions associated with ataxia were absent.

Discussion

This is an unusual presentation; the absence of manifest neuropathy and normal neuroimaging rendered CANVAS unlikely. However, persistent oscillopsia, bilateral vestibular loss, mild cerebellar ataxia, and recurrent cough spells despite optimal asthma treatment pointed toward an *RFC1*-spectrum disorder. The severity of the cough spells was notable in the context of moderate asthma. Up to 64% of patients with CANVAS present with paroxysmal cough, whereas vermis atrophy is found in 80%.^{2,3,5,6} Reduced SNAP in the sural nerves and a sural/radial ratio (SRAR) of 0.2 are abnormal; however, normal SNAP values in other peripheral nerves are not compatible with neuropathy. Of note, the value of SRAR as an indicator of neuropathy is limited and questioned.⁷ In comparison, another patient with a *RFC1*-spectrum disorder displayed cerebellar ataxia, vermis atrophy and recurrent episodes of dizziness diagnosed as benign paroxysmal positional vertigo (BPPV) but with preserved vestibulo-ocular reflex (VOR).⁸ That case and ours suggest that common neurological conditions, such as an acute vestibular syndrome and BPPV, may unmask CANVAS *forme fruste*. Taken together, a careful assessment is warranted in the context of uncompensated acute vestibular syndromes.

Acknowledgment

The authors are grateful to Dr Kaveh Pourhamidi for the neurophysiological assessments and to Dr Maria Pekkari for referring the patient. Computations were enabled by resources in project sens2023617 provided by the National Academic Infrastructure for Supercomputing in Sweden (NAISS) at UPPMAX, funded by the Swedish Research Council through grant agreement no. 2022-06725.

Author Contributions

L. Verrecchia: drafting/revision of the manuscript for content, including medical writing for content; major role in the acquisition of data; study concept or design; analysis or interpretation of data. V. Alm: drafting/revision of the manuscript for content, including medical writing for content; major role in the acquisition of data; analysis or interpretation of data. H. Thonberg: drafting/revision of the manuscript for content, including medical writing for content; analysis or interpretation of data. F. Lenner: major role in the acquisition of data; analysis or interpretation of data. A. Paivandy: major role in the acquisition of data; analysis or interpretation of data. L. Feuk: major role in the acquisition of data; analysis or interpretation of data. A. Lindstrand: major role in the acquisition of data; analysis or interpretation of data. D. Nilsson: drafting/revision of the manuscript for content, including medical writing for content; major role in the acquisition of data; analysis or interpretation of data. M. Paucar: drafting/revision of the manuscript for content, including medical writing for content; major role in the acquisition of data; study concept or design; analysis or interpretation of data.

Study Funding

M. Paucar's research was supported by the Promobilia Foundation and by Region Stockholm.

Disclosure

The authors report no relevant disclosures. Go to [Neurology.org/NG](https://www.neurology.org/NG) for full disclosures.

Publication History

Received by *Neurology: Genetics* July 15, 2024. Accepted in final form November 27, 2024. Submitted and externally peer reviewed. The handling editor was Associate Editor Alexandra Durr, MD, PhD.

References

1. Bronstein AM, Mossman S, Luxon LM. The neck-eye reflex in patients with reduced vestibular and optokinetic function. *Brain*. 1991;114(Pt 1A):1-11. doi:10.1093/oxfordjournals.brain.a101851
2. Cortese A, Simone R, Sullivan R, et al. Biallelic expansion of an intronic repeat in RFC1 is a common cause of late-onset ataxia. *Nat Genet*. 2019;51(4):649-658. doi:10.1038/s41588-019-0372-4
3. About Syriani D, Wong D, Andani S, et al. Prevalence of RFC1-mediated spinocerebellar ataxia in a North American ataxia cohort. *Neurol Genet*. 2020;6(3):e440. doi:10.1212/NXG.0000000000000440
4. Cortese A, Curro R, Vegezzi E, Yau WY, Houlden H, Reilly MM. Cerebellar ataxia, neuropathy and vestibular areflexia syndrome (CANVAS): genetic and clinical aspects. *Pract Neurol*. 2022;22(1):14-18. doi:10.1136/practneurol-2020-002822
5. RFC1 Study Group, Traschütz A, Cortese A, et al. Natural history, phenotypic spectrum, and discriminative features of multisystemic RFC1 disease. *Neurology*. 2021;96(9):e1369-e1382. doi:10.1212/WNL.00000000000011528
6. Cortese A, Reilly MM, Houlden H. RFC1 CANVAS/spectrum disorder. 2020 Nov 25. In: Adam MP, Everman DB, Mirzaa GM, et al. eds. *GeneReviews® [Internet]*. University of Washington:1993-2023. 2020. ncbi.nlm.nih.gov/books/NBK564656/
7. Overbeek BU, van Alfen N, Bor JA, Zwarts MJ. Sural/radial nerve amplitude ratio: reference values in healthy subjects. *Muscle Nerve*. 2005;32(5):613-618. doi:10.1002/mus.20421
8. Kulshreshtha D, Ganguly J, Jog M. Expanding the clinical spectrum of RFC1 gene mutations. *J Mov Disord*. 2022;15(2):167-170. doi:10.14802/jmd.21117